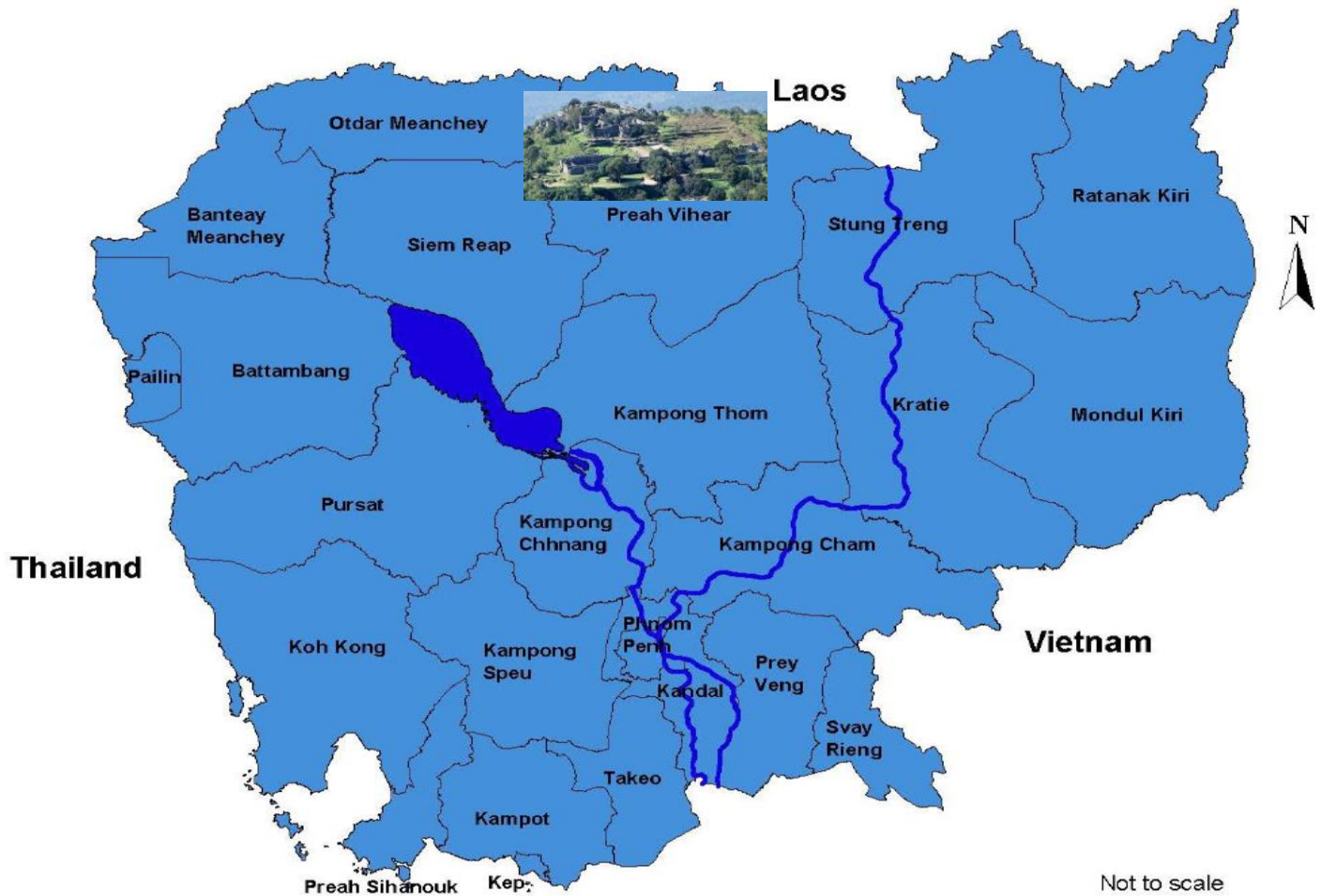


## OUTREACH SURGICAL MISSION,

# PREAH VIHEAR PROVINCIAL HOSPITAL, CAMBODIA

**JUNE 11-14. 2015**



Preah Vihear province is located in northern Cambodia, 294 km from Phnom Penh accessed by National Road No. 6 and 62.

The current population in this province is about 235,355 people or 1.1% of the country's total population (14,676,607 persons in Cambodia - Cambodia inter census population November 2013). The population density is therefore 11.64 people per square km.

The province borders Stung Treng province to the east, Siem Reap province and Oddar Meanchey province to the west, Thailand and Laos to the north and Kampong Thom province to the south. While much of the province is extremely remote and strongly forested, and the province is one of least populated in Cambodia, it is home to three impressive legacies from the Angkorian era: the mountain temple of Prasat Preah Vihear, which is well known as a World Heritage Site, the 10th-century capital of Koh Ker and the mighty Preah Khan. These legacies attract many local and international tourists every year.

The provincial economy is 85% based on farming and the remaining 15% based on fishing and other sectors. Recently, because of its border with Thailand, international trade has increased slightly,

becoming another important sector for the province's economy. The economy and infrastructure of the province was also substantially destroyed during the Khmer Rouge regime and needs therefore a whole new stable backbone.

Related to its Health System, the provincial health net consists of a referral Hospital, named 16 Makara, and 11 Health Centers. It is one of the remote areas in Cambodia, where health services are limited, both in facility and techniques. Moreover, a surgical specialty services are lacking in this province.

Referring to such a dire need for surgical medical care, an outreach surgical mission, initiated by a collaboration of the National Pediatric Hospital and the Connecting with Cambodia Project-NextSteps organization, and supported by the generous contribution of GECKO, Kinderhilfe Südostasien e.V., Erfurt, Germany, was conducted on June 11-14, 2015 at Preah Vihear-16 Makara provincial hospital. This mission aimed to treat children and young adults who suffer from limb and maxillofacial congenital anomalies, burn contractures, and general pediatric surgery, whose family could not otherwise afford treatment elsewhere.



The organization and activities of the outreach surgical mission are following outlines:

**I- Surgical Team / Resources:**

A total of 28 surgical team members from the National Pediatric Hospital, other hospitals and international volunteers were involved in the mission. These included 7 surgeons, 2 anesthetist doctors, 7 anesthetist nurses, 3 scrub nurses and 2 ward nurses. We also had 4 surgical trainees joining our mission as assistants.

**Table 1: Composition of Surgical Team Members**

	<b>Cambodian Team</b>	<b>International Team</b>	<b>Miscellaneous</b>	<b>Total</b>
<b>Surgeons</b>	4 (NPH)	1 volunteer Surgeon	Laurent W	5
<b>Scrub Nurses</b>	3 (NPH)			3
<b>Anesthetist Doctor</b>	2 (1 NPH + 1 volunt.)			2
<b>Anesthetist Nurse</b>	7 (3 NPH + 4volunt.)			7
<b>Ward nurse</b>	1 (NPH)	1 volunteer nurse	Nicole	2
<b>Social worker</b>	N/A			
<b>Coordinator</b>	1 (NPH)			1
<b>Other Surgeons (DU)</b>	2 (Volunteers)			2
<b>Surgical Trainees (DES)</b>	3 (volunteers)			3
<b>Visitors</b>				
<b>Medical Student</b>	1 Japanese Volunteer		YUKIKO	1
<b>Non-medical person</b>	2 volunteers			2
<b>Total</b>	26 persons	<b>2</b>		<b>28</b>

**II- Activities and achievement:**

- 1- In the morning of June 11, 2015, we departed Phnom Penh and reached Preah Vihear Provincial hospital at 2:00 pm on the same day.
- 2- At 2:30 pm, we started working by dividing the team in 2 groups:
  - a. One group (Anesthetists) took care of the preparation of the operating theatres, surgical wards, recovery room and post-operative sites.
  - b. The other group started to do patient triage, clinical consultation, screening patients for surgery for the following two days. At the end of the day, we had a meeting to coordinate all detailed works to be done in the next following 2 days: **Who doing What.**
- 3- Timetable for the 2 working days was designed to start from 7:00am to 5 pm. However, we could not end each day before 8 pm. Surgical procedures were conducted in 2 operating theatres.
- 4- Within the mission, we have seen 126 patients coming for consultations and seeking medical advice. Of these, 52 patients/cases underwent various surgical procedures. For safety reasons, six cases with very severe deformity and impairment where surgical procedures would be complicated, were advised to go to the main surgical centers at national hospital level for treatment.

- 5- Patients who received surgical operations included Cleft lip-palate (5 cases), limb deformity (clubfoot, amniotic band) (11 cases), soft tissue tumors (4 cases), Burn contractures of limbs (14), trauma aftermath (2 cases), and surgery around inguinal regions (16 cases).
- 6- All surgical procedures, either under local, regional, or general anesthesia were safe and smooth. Immediate post operative conditions found no complications.
- 7- On the fourth day prior to our departure back to Phnom Penh, an attentive ward round was conducted involving both parties - the mission surgeons and local surgeons, where all notes of procedures, post-operative wound care and follow-up tasks were communicated and transferred. We found this is critical in terms of teaching, exchanging skills, and most importantly for the safety of our patients.
- 8- On June 14, 2015, our surgical team returned safely back to Phnom Penh.

**III- Collaborations:**

The Local surgical team and hospital management were very helpful facilitating our mission. They helped us with collecting and registering patients prior to mission dates. They also helped in preparing the mission site, both facility and staff. We exchanged technical experiences with them, and learned of the practical things they have been using with their limited resources to cope with their struggling working conditions. Local surgeons will continue taking care of operated patients after the mission so that complete healing and follow-up is achieved. We are grateful for such an invaluable collaboration which is critical to the success of our surgical mission.

**IV- Conclusion:**

The mission was considered very successful. Varieties of fifty-two surgical procedures were conducted safely with good results. All patients who underwent surgical procedures were satisfied with the results. They were smiling, hopeful, and very grateful to the surgical team. Patient families and local staff have asked if we could conduct such a surgical mission annually to their province. We thanked them for such a wonderful collaboration. Beneficiaries of such an outreach surgical mission are those who suffered from congenital and acquired anomalies, deformities, and general surgical sickness who otherwise could not afford or have no chance to receive surgery elsewhere in their whole life.

**V- Acknowledgement:**

As the chief of mission, I would like to express my warm gratitude to all mission members, local and internationals, volunteers, Preah Vihear surgical team, the National Pediatric Hospital Board of Directors, Preah Vihear Hospital Director and Provincial Health department for their direct and indirect contribution to this humanitarian surgical mission. We all are grateful to the Connecting with Cambodia project- NextSteps Organization, and particularly to GECKO, Kinderhilfe Südostasien e.V., Erfurt, Germany who kindly, fully and invaluable support this mission.

REPORTED on November 1, 2015

**Vuthy CHHOEURN**

**OUTREACH SURGICAL MISSION**  
**PREAH VIHEAR PROVINCIAL HOSPITAL, CAMBODIA**  
**JUNE 11-14, 2015**  
**HIGHLIGHTED ACTIVITIES**



**Fig 3: NPH surgical Team on its arrival at Preah Vihear Provincial Hospital**



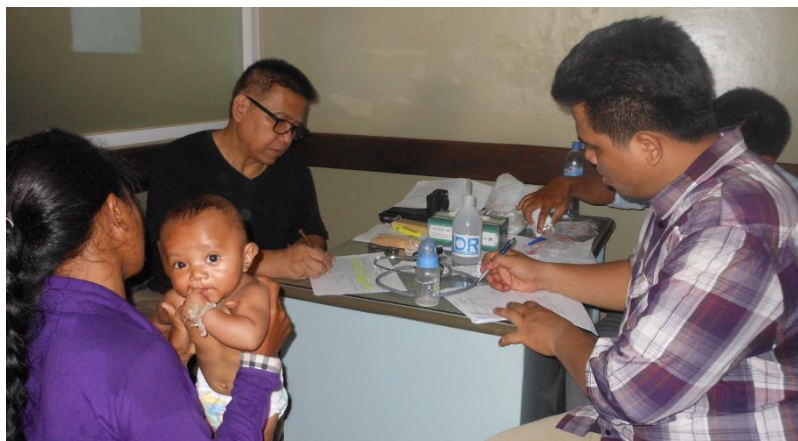**Fig 4: Waiting for consultation at mission site**

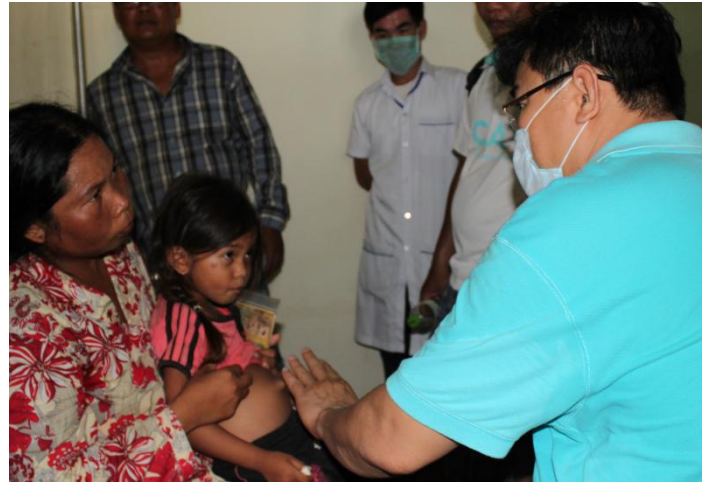
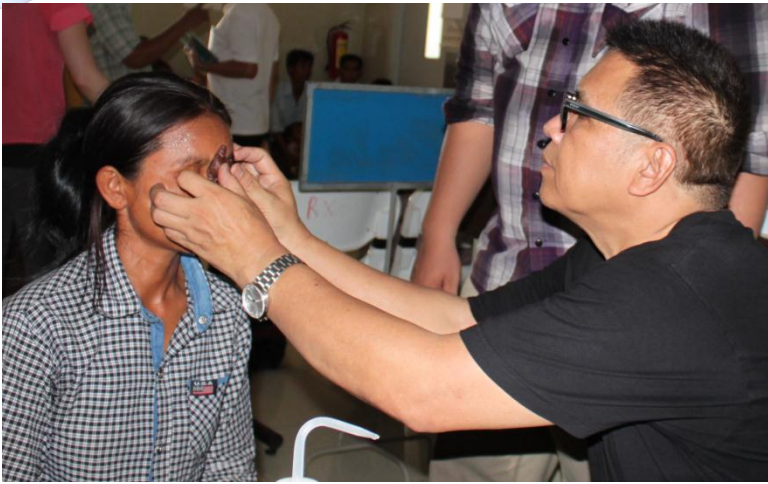
**Fig 5: Patient triage**

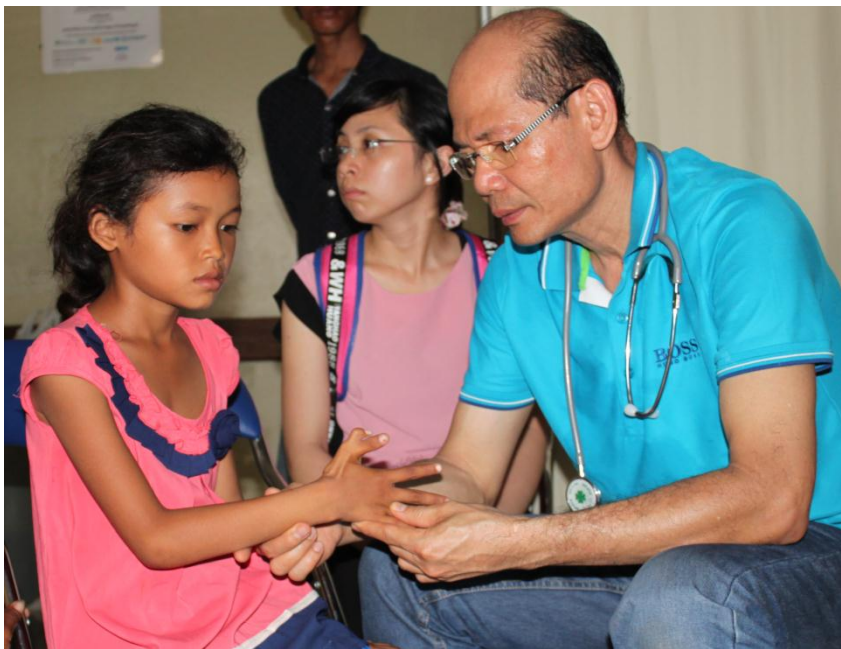

**Fig 6: Anesthetic consultation on Day 1: 11 June 2015**





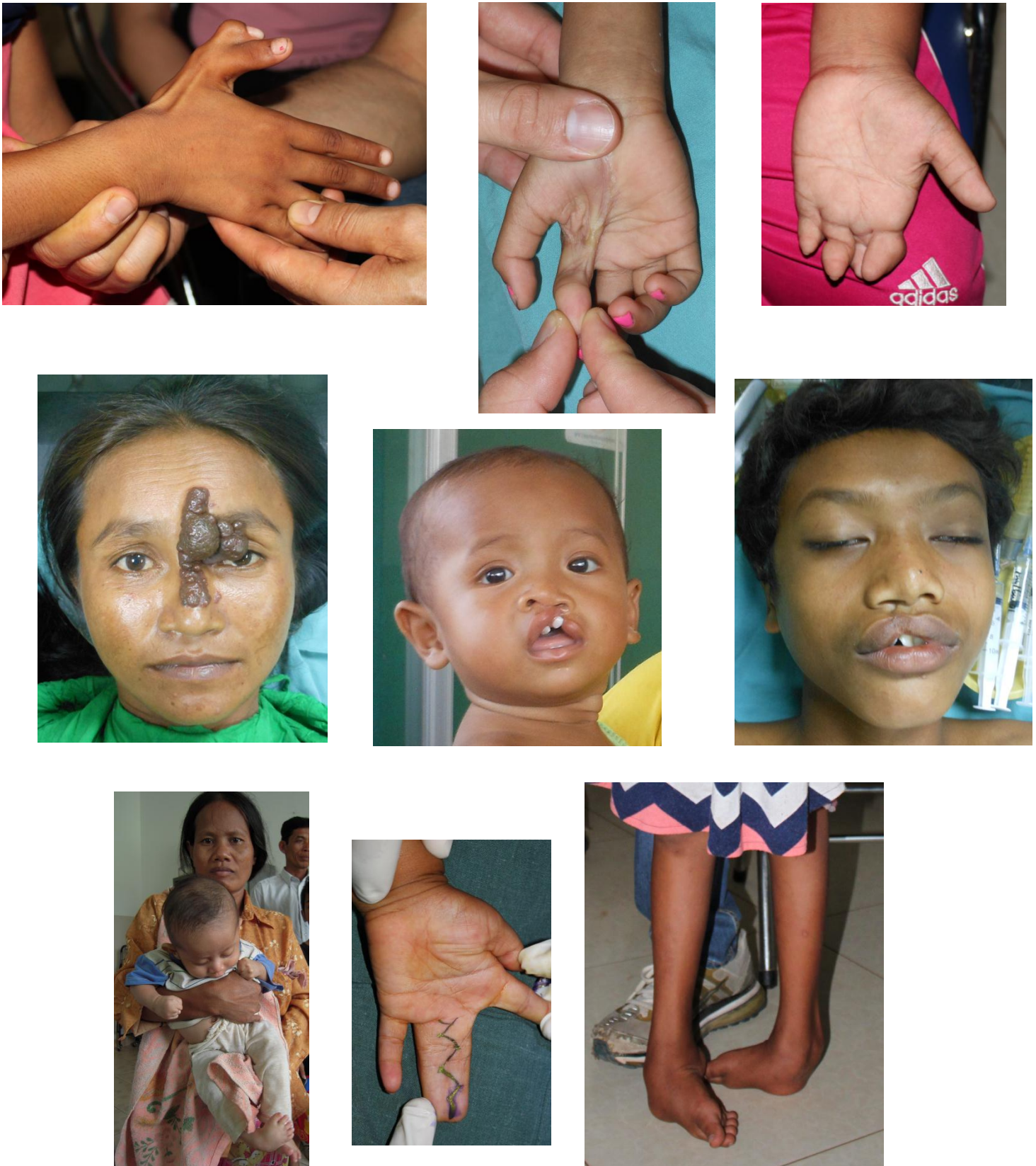**Fig 7: Dr Long vanna and Dr Choeu Hor are giving consultation to patient: June 11 2015**



**Fig 8: Patient consultation: June 11 2015**



**Fig 9: Team coordination Meeting**



**Fig 10: Varieties of surgical procedures conducting during surgical mission**



Fig 11: Pre-operative room- Waiting for surgery

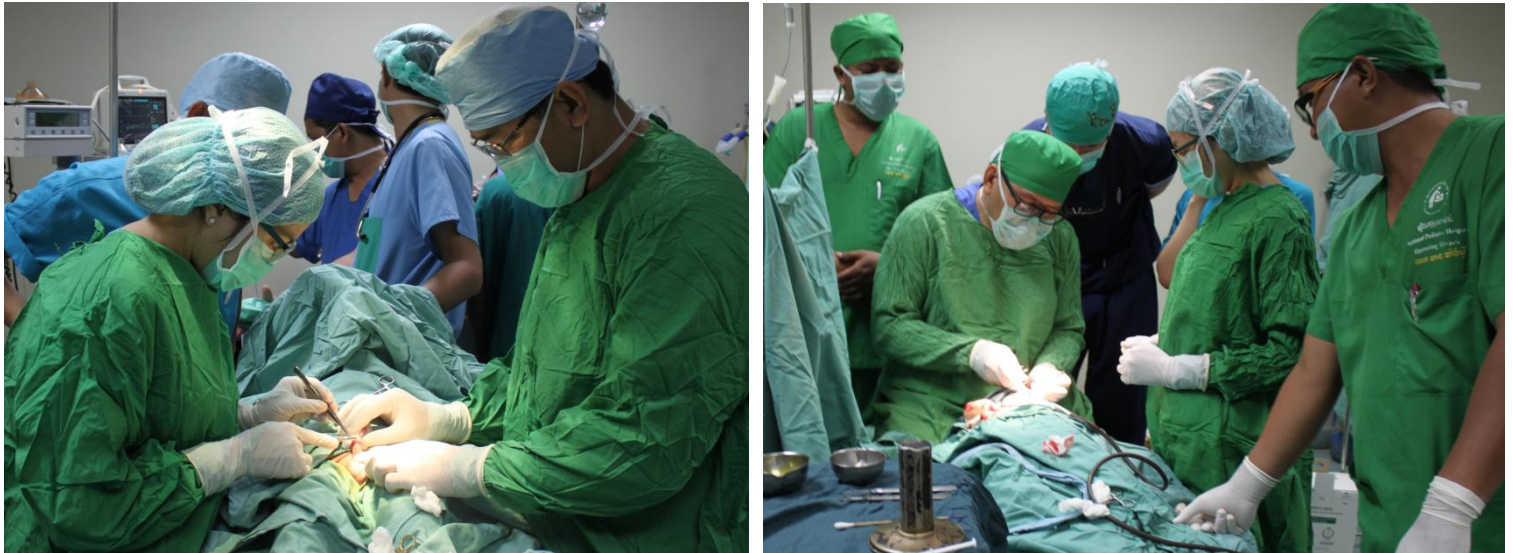

Fig 12: Surgical procedures being conducted by Dr Vanna and Dr CHOEU Hor

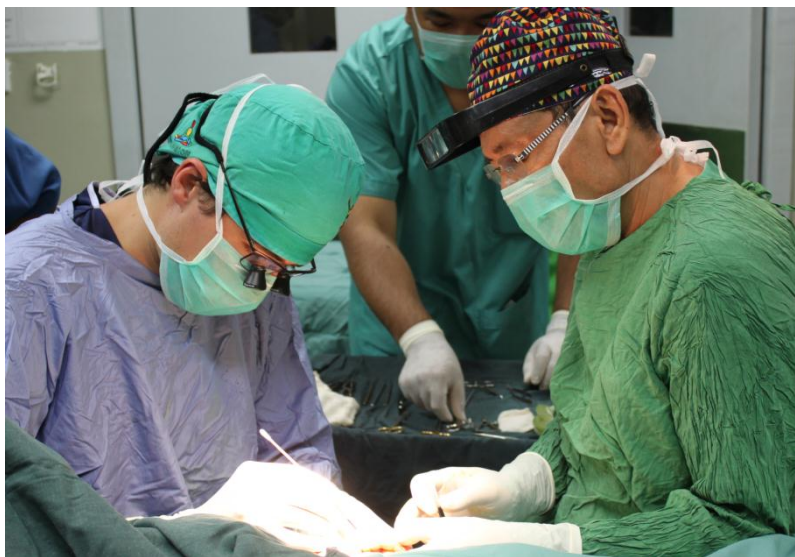

Fig 13: Dr Vuthy and Laurent are performing a syndactyly release and reconstruction

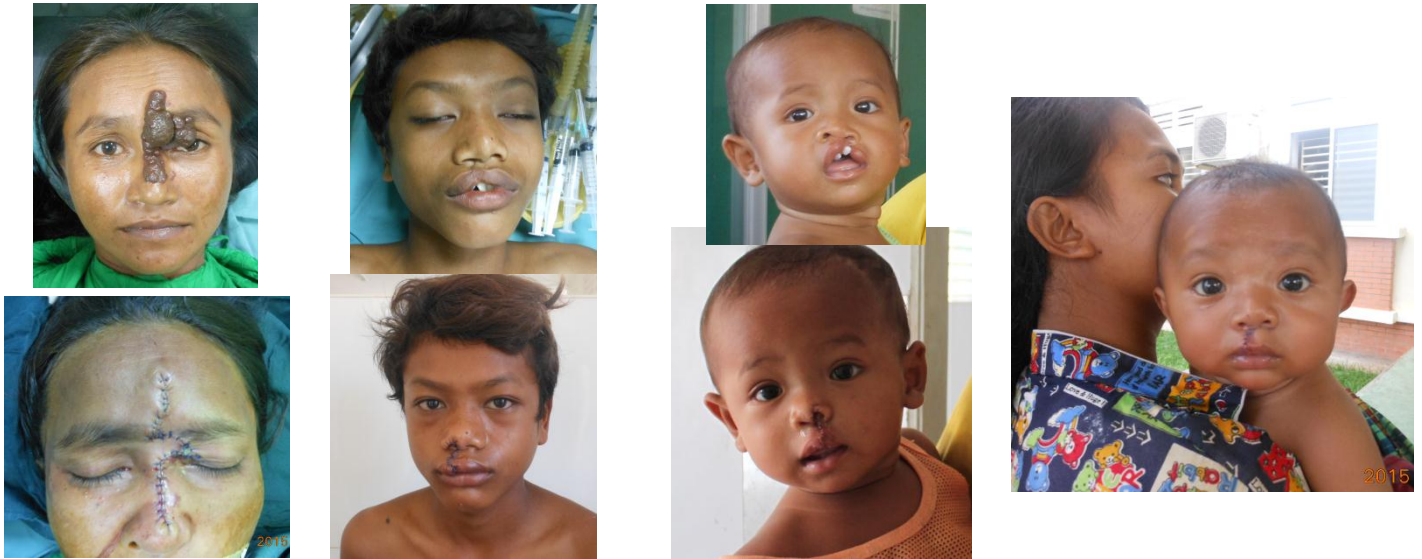

Fig 14: Pre and Post-operative cases

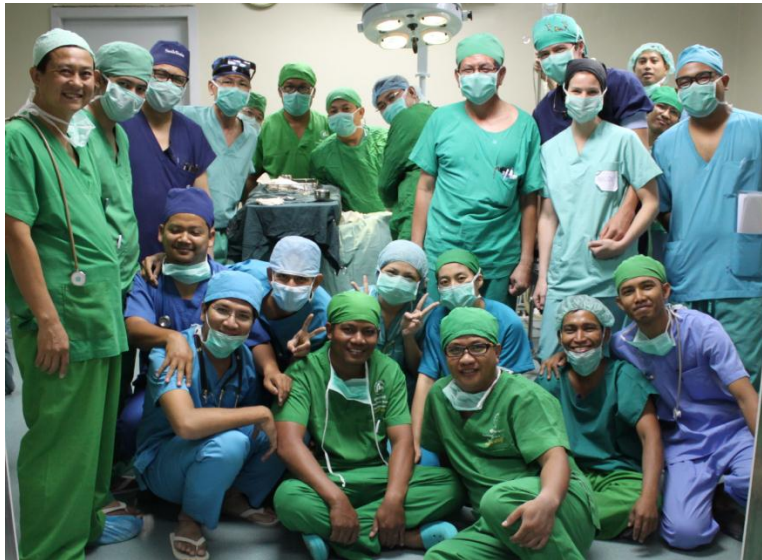

Fig 15: Missionary Surgical Team



Fig 16: Hand over patient care and follow-up to local surgeon before departure

