

**Brief Report**  
**Outreach Surgical Mission**  
**Kratie Referral Hospital, Kratie Province**  
**December 11-14, 2011**



**Date: December 11-14, 2011**  
**Mission Site: Kratie Provincial Hospital**  
**Team: National Pediatric Surgical Team**

Reported by CHHOEURN Vuthy M.D.  
Department of Surgery  
National Pediatric Hospital, Phnom Penh, Cambodia  
Tel: (855) 12 962 617, Fax: (855) 23 880 475,  
Email: [vuthy.chhoeurn@gmail.com](mailto:vuthy.chhoeurn@gmail.com)

## **I- Aim of the Mission:**

- 1- Providing first-hand surgical care to vulnerable children living in Kratie province and surrounding area, suffering from maxillofacial and limb congenital defect, burn contractures, trauma and war wound aftermath, and who have had no access or less access to surgical service needed.
- 2- Providing “supervising surgical training” to trainees and residents, involving in (University Diploma) pediatric surgery training program
- 3- Providing On-the-Job-Training to local surgical team to get familiar with Pediatric Surgical Operations

## **II- Team Members:**

- 1- Team leader: Vuthy Chhoeurn
- 2- Local Team members: 2 surgeons, 3 anesthesiologists, 5 residents/Assistants, 3 Operating nurses and 2 ward nurses, from the National Pediatric Hospital Phnom Penh
- 3- Volunteers: 2 surgeons, 2 residents/assistants, 4 nurses, 2 Speech Pathologists (from United Kingdom, Korea and Taiwan)



**Patients-Families, Waiting for Registration and Consultation**

### **III- Activities in Brief:**

- December 11, 2011:
  - Departure trip from the National Pediatric Hospital Surgical Team from Phnom Penh to Kratie Province,
  - Setting up- Preparing surgical equipment and facility for the next-day surgical operation
- December 12, 2011: Doing consultation and Performing Surgical operations.
  - We have seen in this day 154 patients (Children and Adults) in out-patient clinic, and
  - Performing 26 surgical operations (9 cleft lip-palate repairs, 11 reconstructive surgeries and 4 orthopaedic surgeries).
  - We finished the day with ward-rounding to see all operated patients, making sure that they were all in closed follow-up, both general condition and surgical wounds
- December 13, 2011:
  - The day was started with ward-round,
  - Continuing consultation for new patients: 17 new consultations
  - Performing 23 more surgical operations including: 7 cleft lip-palate patients, 14 reconstructive surgeries (Skin tumors, severe burn contractures, limb deformities), and 2 orthopaedic surgeries.
  - The day was again ending up with evening ward round to see all operated patients.
- December 14, 2011:
  - Ward round, case discussion, making appointment for follow-up,
  - Leaving message and planning of follow-up patient with local doctors.
  - During the mission, we decided to send few difficult cases to Phnom Penh for surgical operation and further care

### **VI- Achievement and Conclusion:**

We have gone through, during the 4-day-outreach-mission with 2 working-days, 171 consultations, 49 surgical operations including 16 Cleft lip-palate surgeries, 28 plastic and reconstructive surgeries, and 5 orthopaedic surgeries. Surgeries were conducted smoothly in two operating theatres, with 4 operating tables. Forty operations were conducted under general anesthesia, and local anesthesia was practiced for the other nine cases. All operated patients went well without any surgery related specific complications. Postoperative care was smooth and effective.

Collaboration with local provincial surgical team and visiting team was very good and fruitful.

The surgical team has been praised by the local government and the hospital that this was a successful mission. The local hospital requested our surgical mission to be continued in the future.



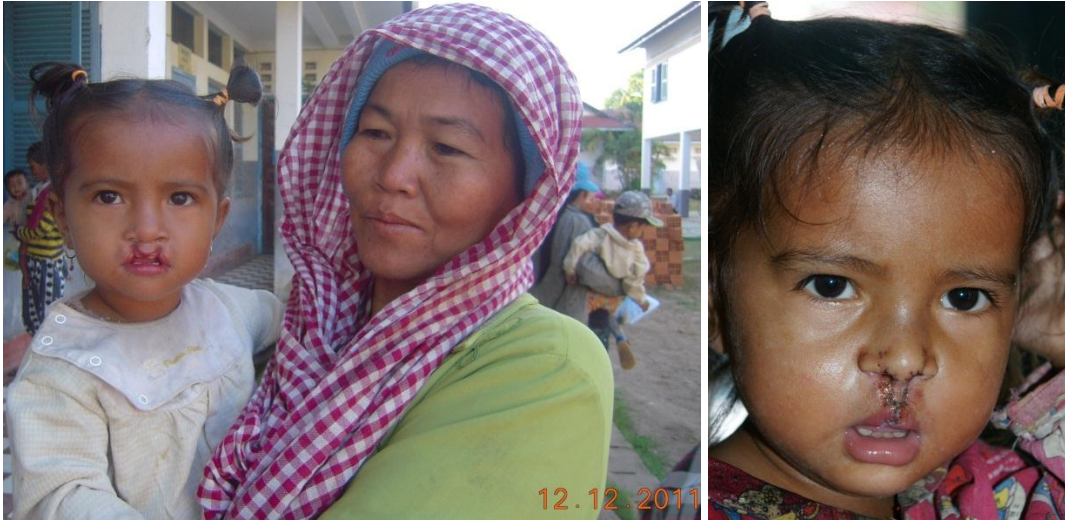**Registration**



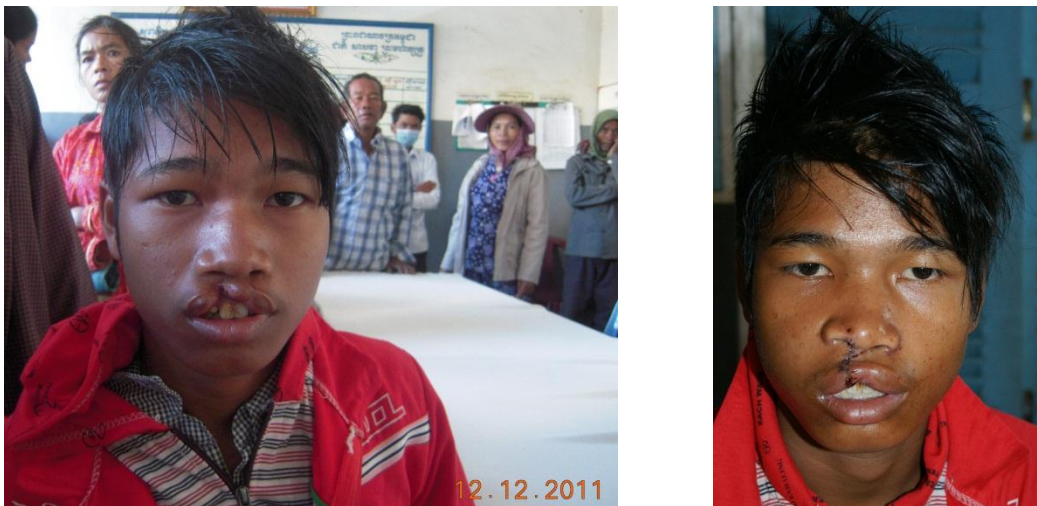**Consultation**



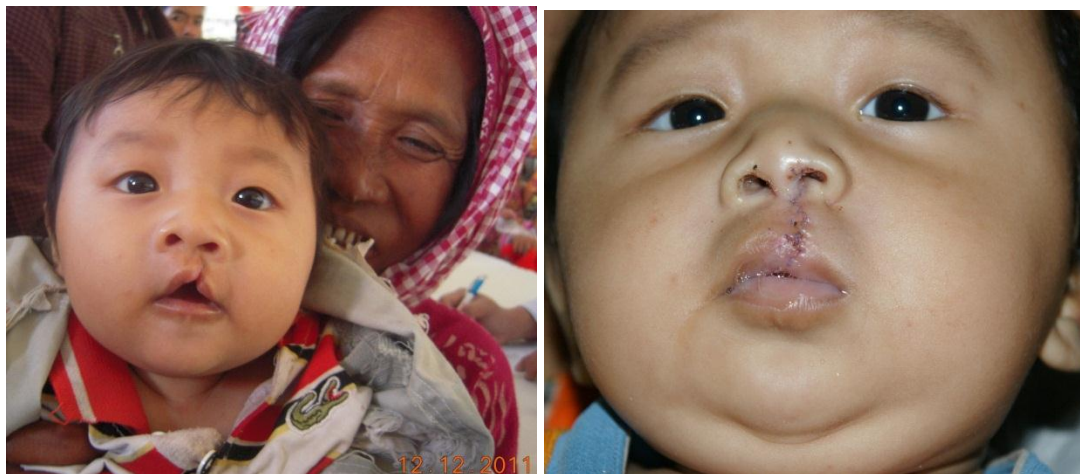**Consultation**



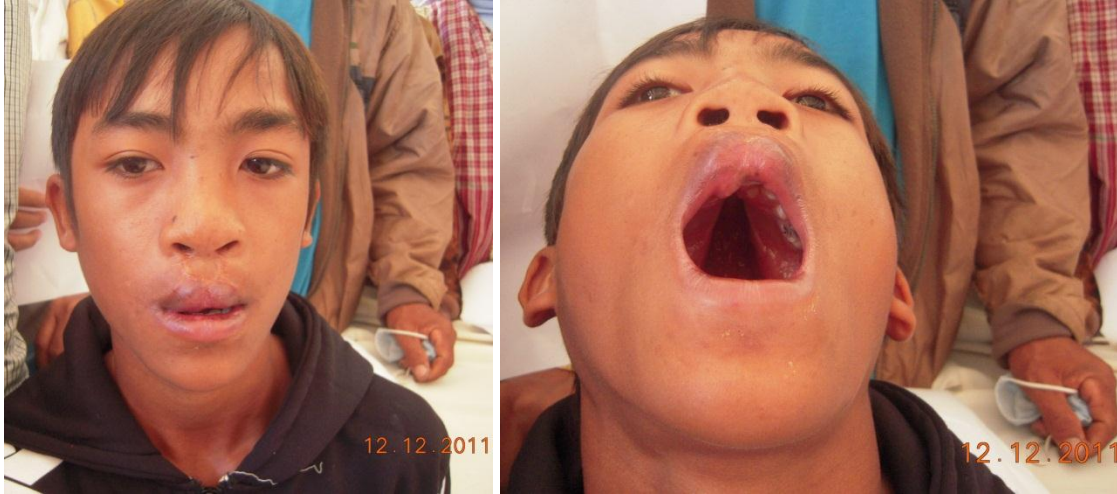**Bilateral Cleft Lip of 4 year-old girl Before and After Lip Repair Surgery**



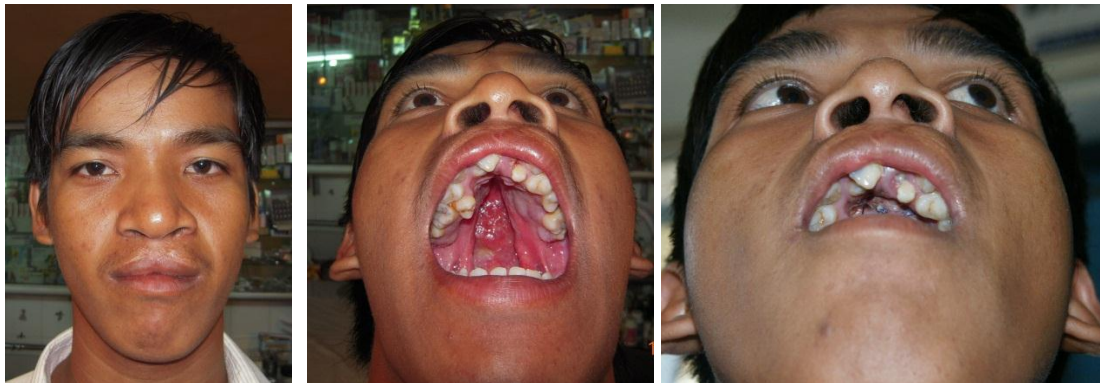**Unilateral Cleft Lip of 17 year-old boy Before and After Lip Repair Surgery**



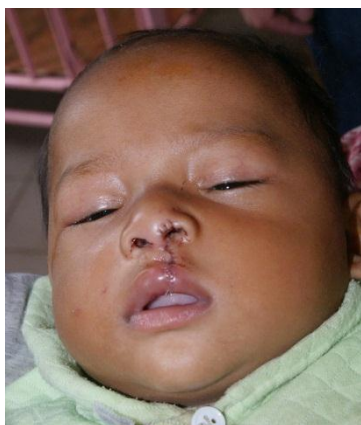**Unilateral Cleft Lip of 1.5 year-old boy Before and After Lip Repair Surgery**



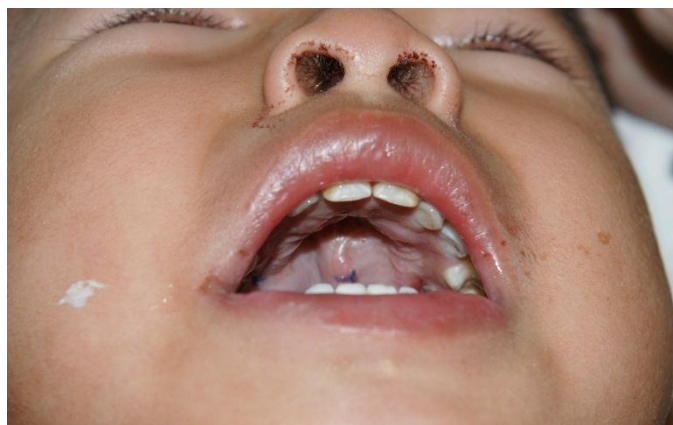**Bilateral Cleft Lip and Palate of 16 year-old boy Before palate Surgery**



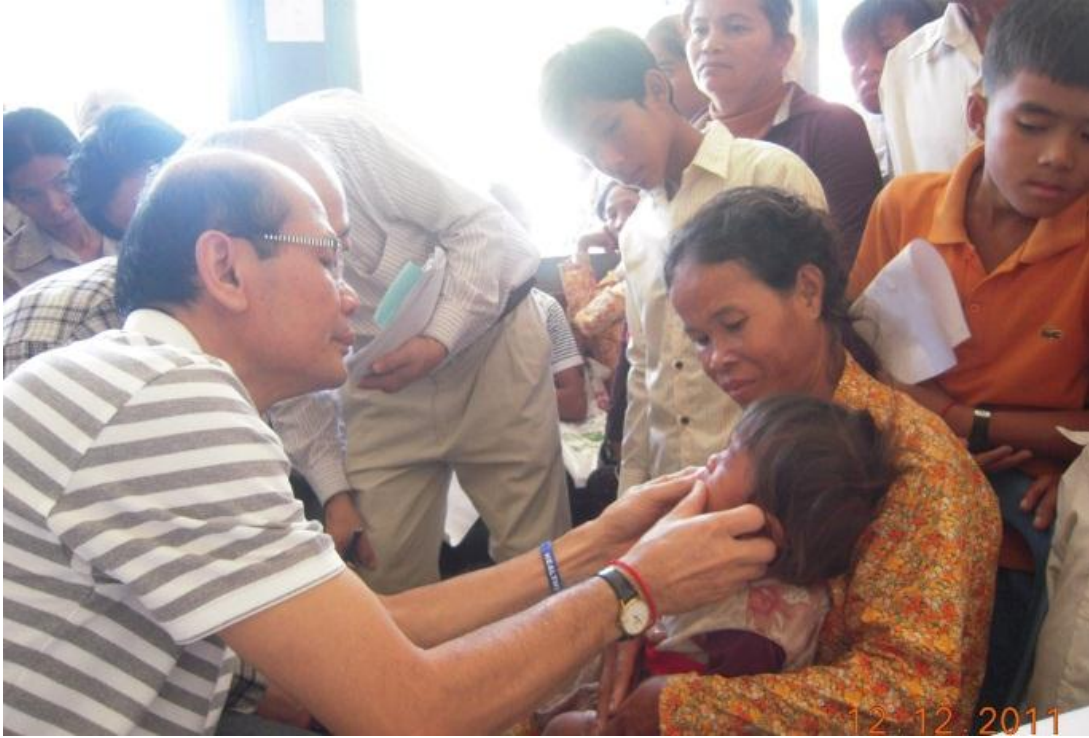**Bilateral Cleft Lip-palate of 25 year-old man Before and After Palatoplasty**



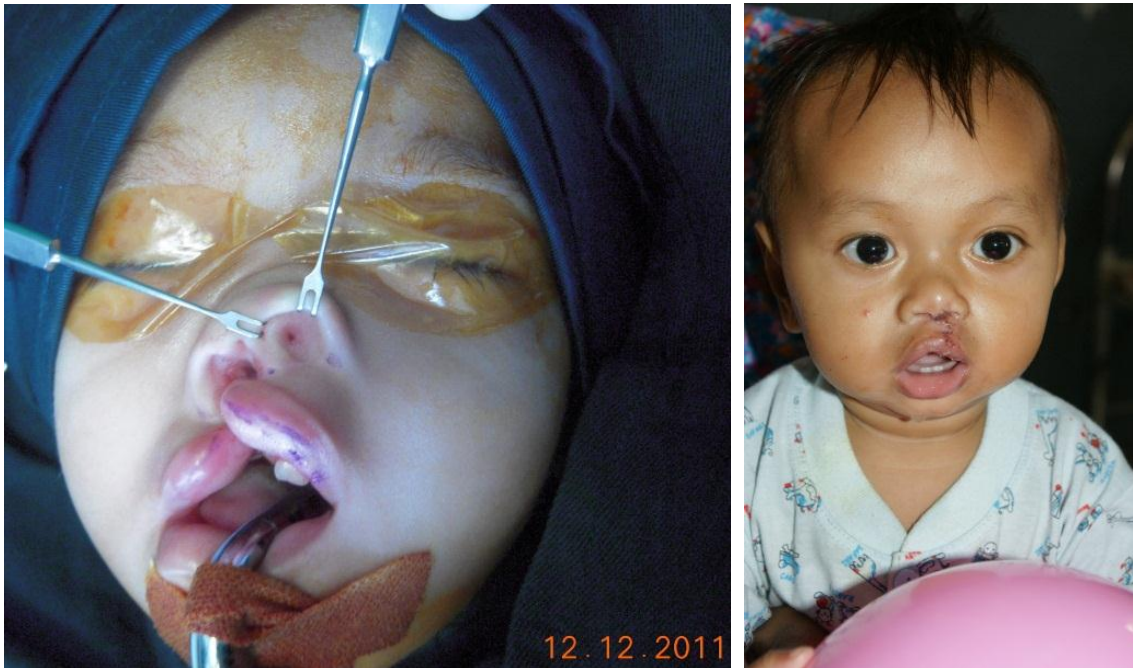**Lip Surgery of 1 year-old boy;**



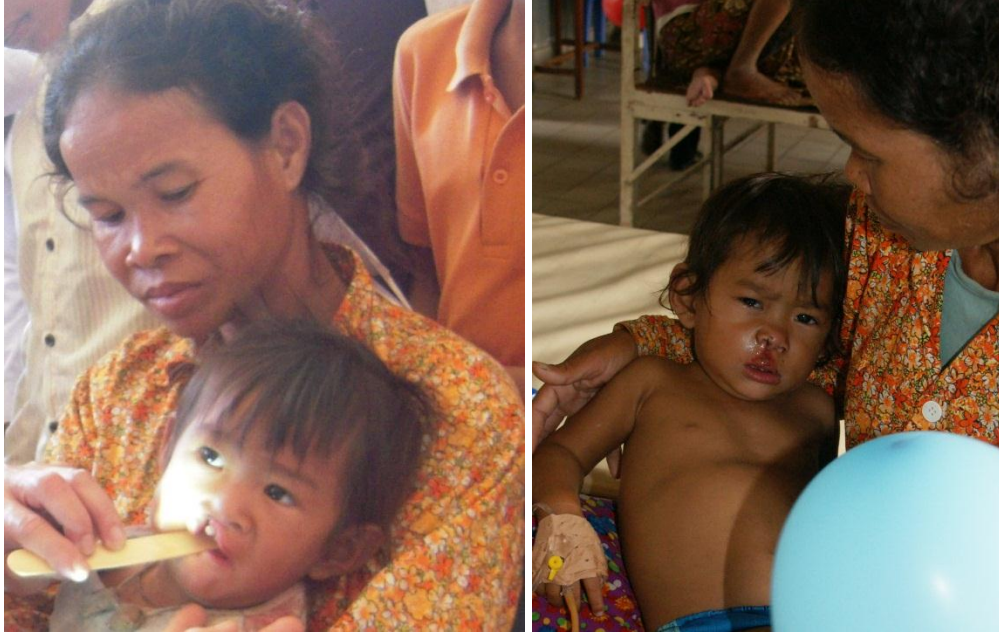**Palatoplasty of 15 month-old bot**



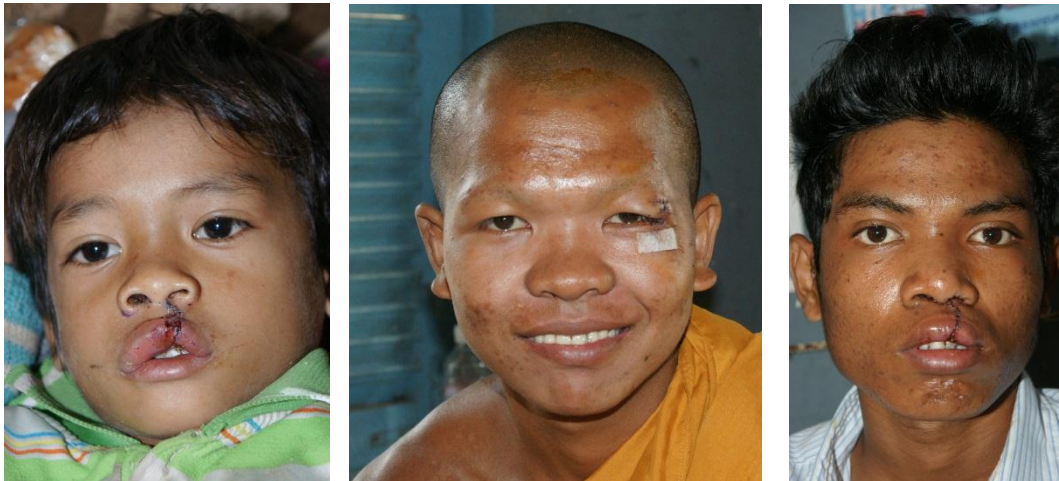**Case discussion with Volunteer for a Cleft difficult case during consultation**




**Unilateral Cleft Lip-Nostril atresia of 8 month-old boy  
Before and After Lip Surgery**



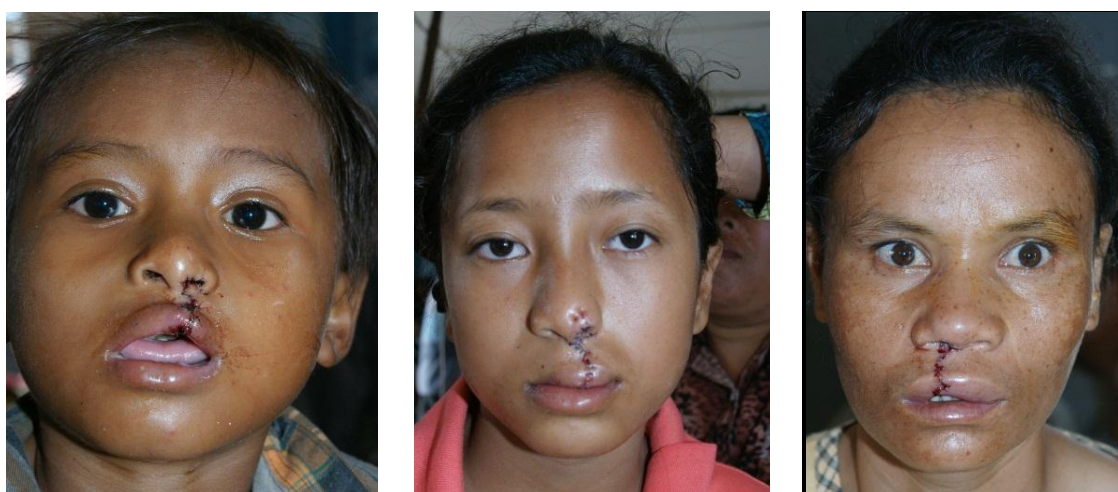**Unilateral Cleft Lip of 3 year-old girl Before and After Lip Repair Surgery**



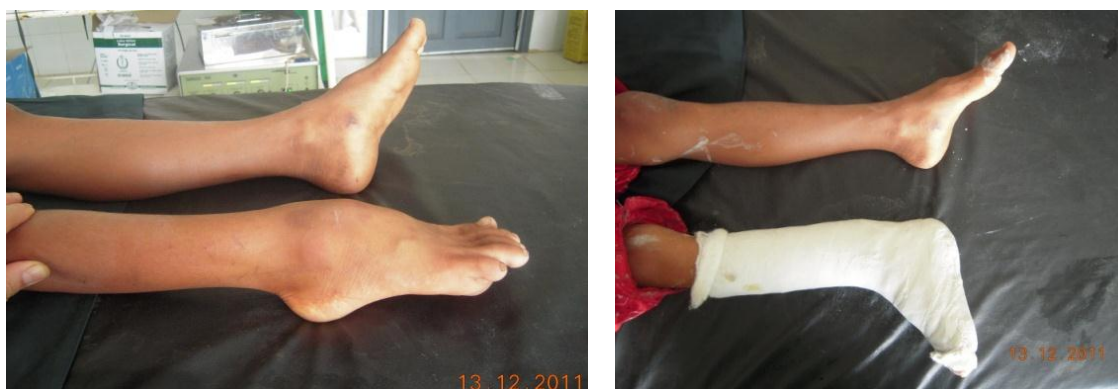**Cleft Lip Surgery: 5 year-old boy, and 20 year-old man (Left & Right), and Post-Traumatic Facial Scar-Eyelid contracture (Middle)**



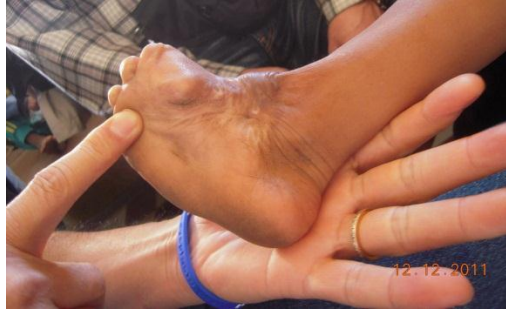**Cleft Lip Surgeries: 22 year-old man, 2 year-old boy, and 16 year-old boy**



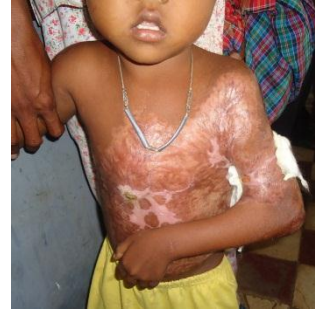**Cleft Lip Surgeries: 6 year-old boy, 15 year-old girl, and 35 year-old woman**



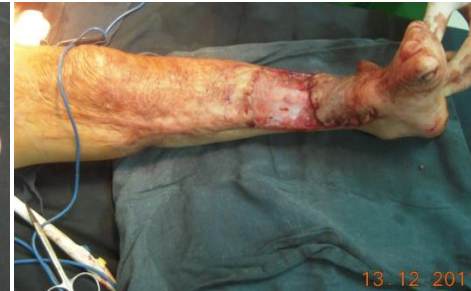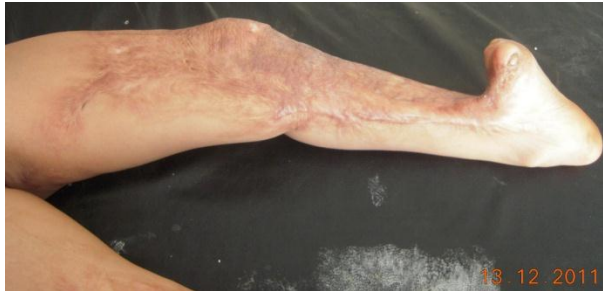Nine year-old boy with Ankle Plantar flexion Contracture (Equinus) secondary to calf infection since he was 3 years old. Percutaneous Tendo AChiles Tenotomy-Casting procedure was performed



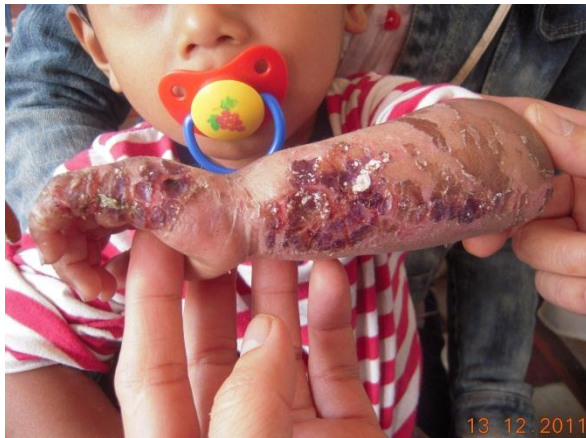**Burn Contracture**



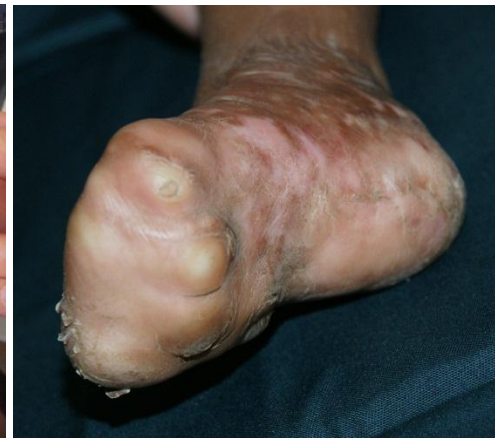**Burn Contracture**



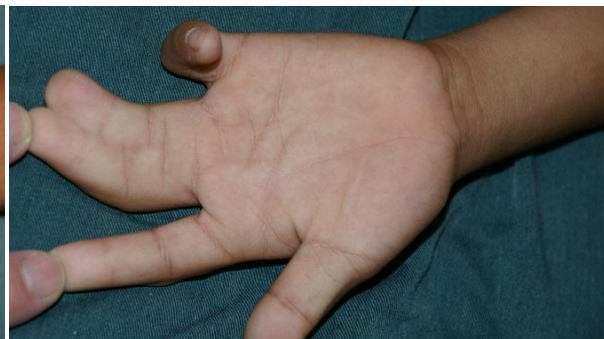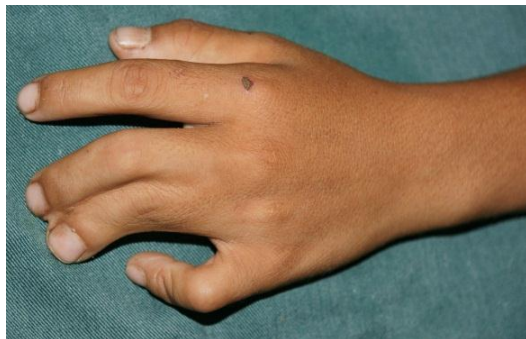Very Severe Burn Ankle flexion Contracture Contracture of a 7 year-old girl, who got burn when she was 2 years old: Before and after Scar Contracture release-Skin Graft procedure.



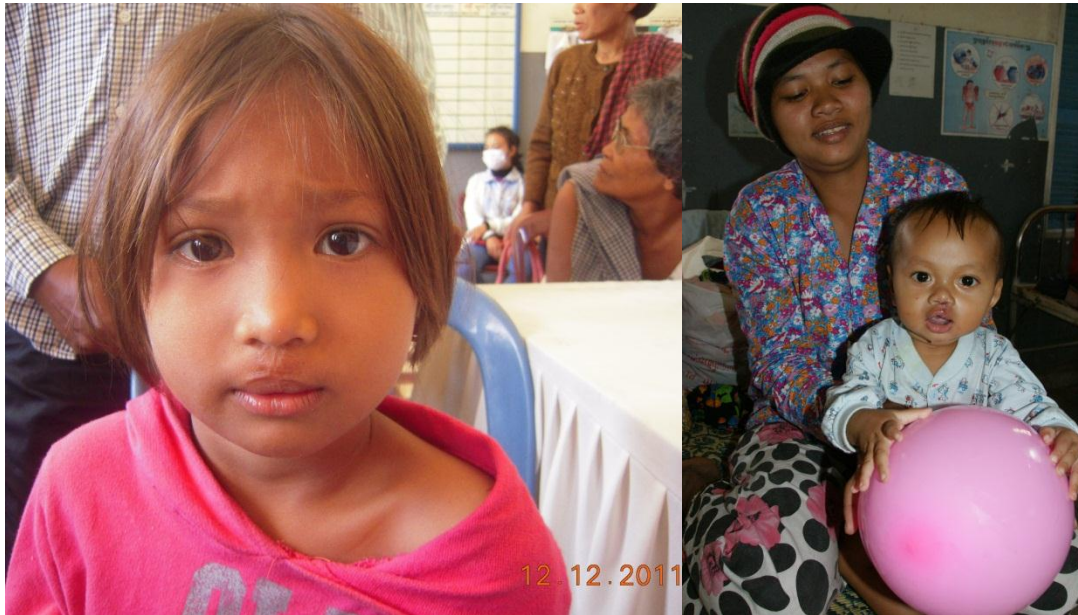**Burn**



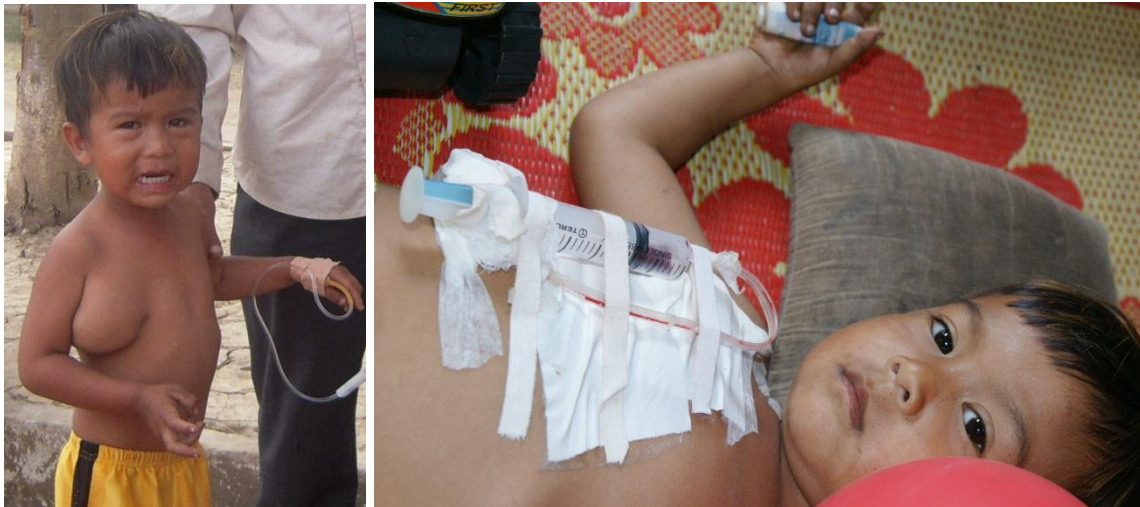**Burn with Toe flexion Contracture**



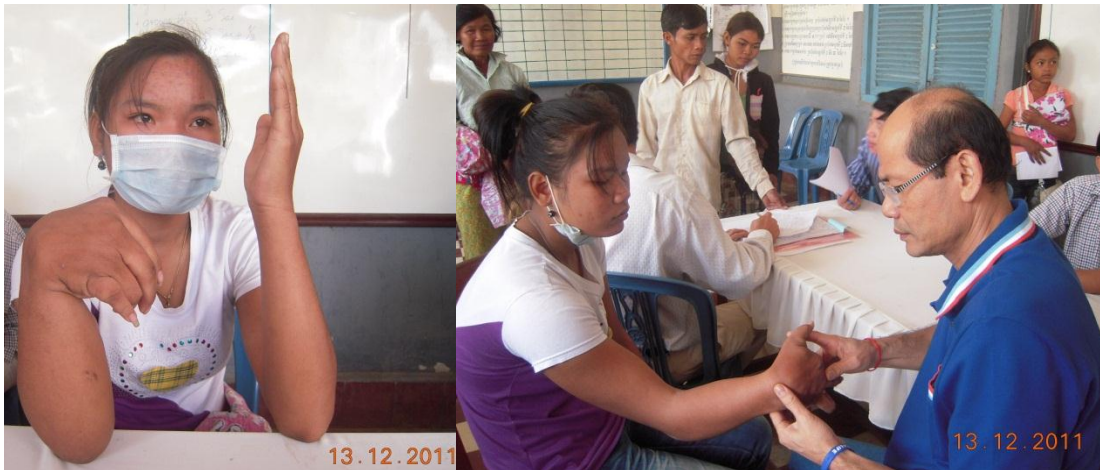**Syndactyly 3<sup>rd</sup>-4<sup>th</sup> finger**



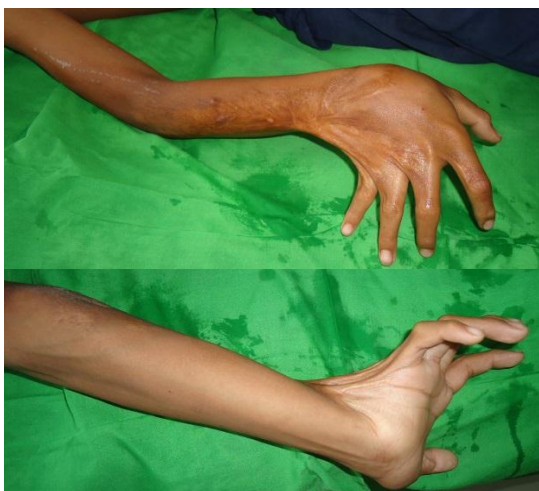**Cleft Lip-palate Surgeries: 6 year-old girl, 2 year-old boy,**



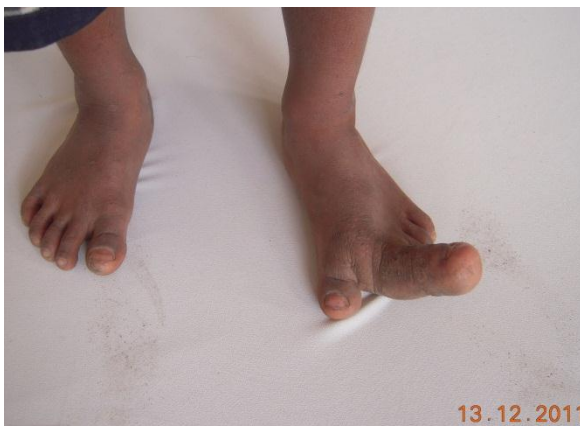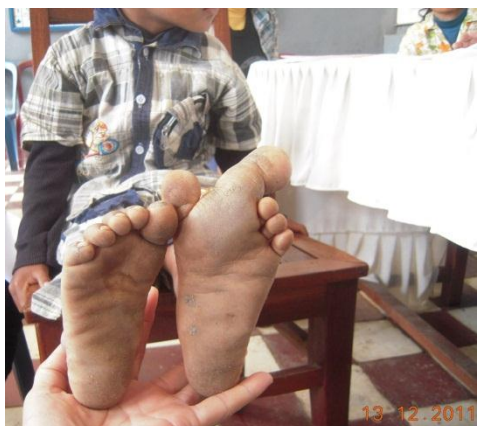**Lymphangioma right armpit and anterior chest wall, before and after surgery**



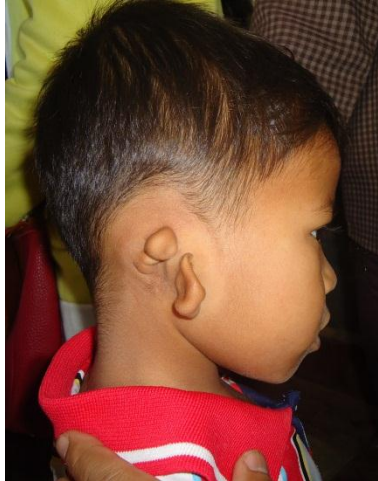**Congenital right wrist contracture**



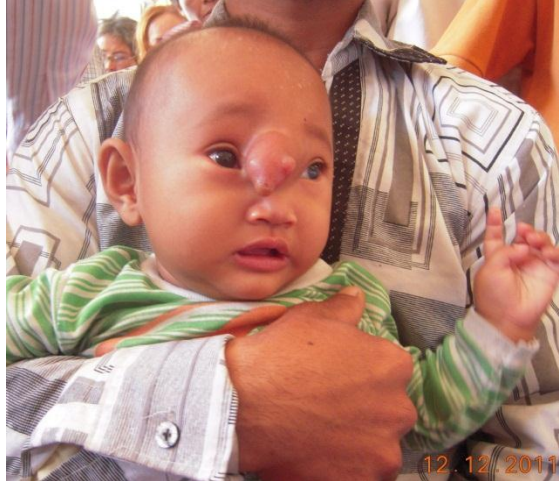**Burn Contracture right wrist before and after surgery**



**Congenital Acromegaly of 2<sup>nd</sup> toe-left**



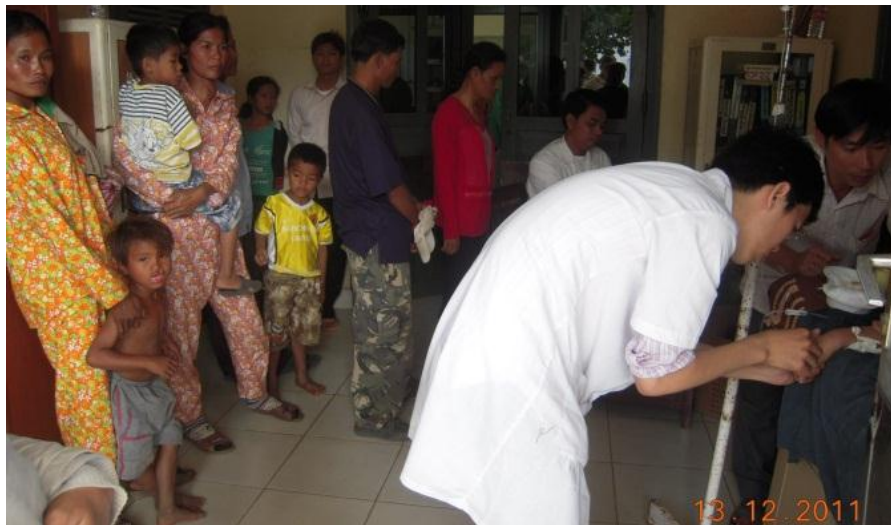**Microtia**



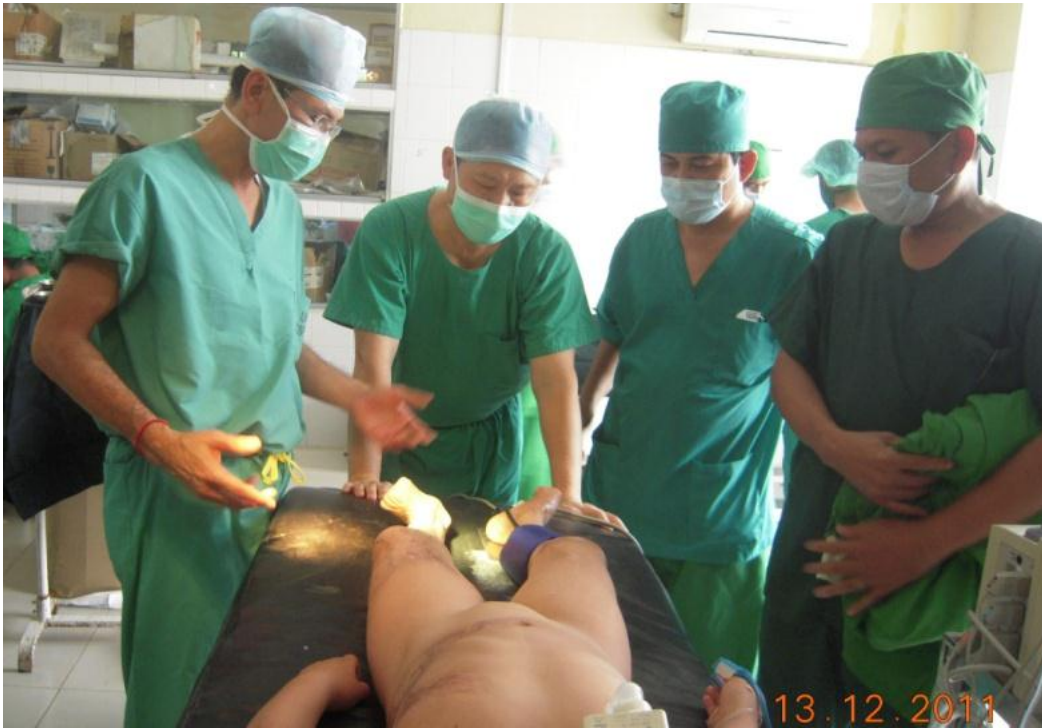**Meningoencephalocele**



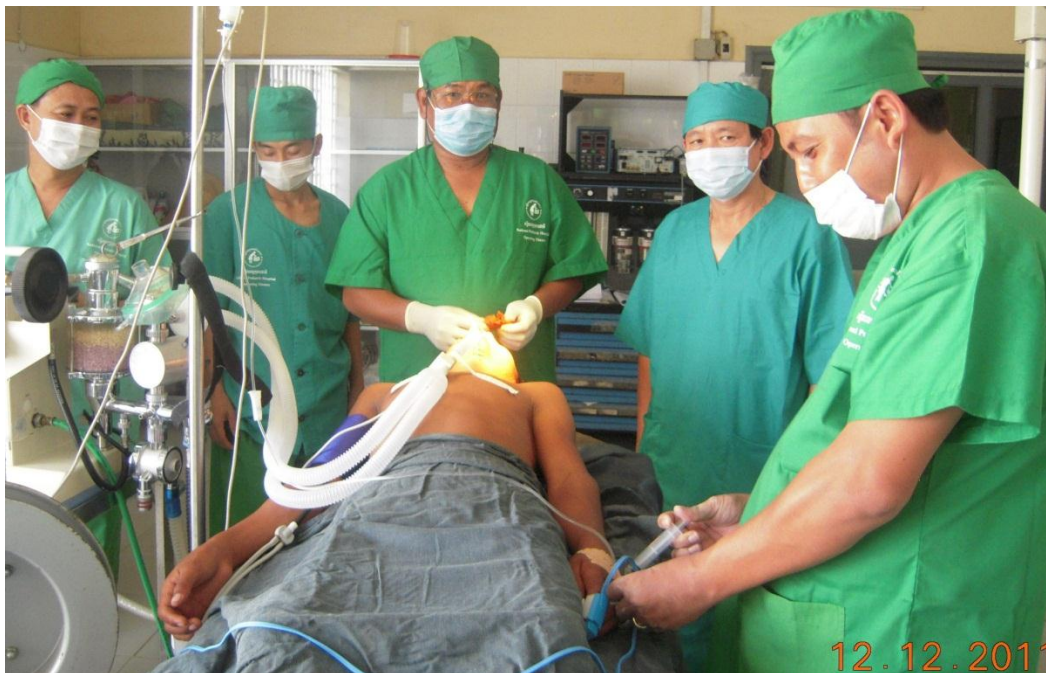**Preoperative Nursing and Patient record**



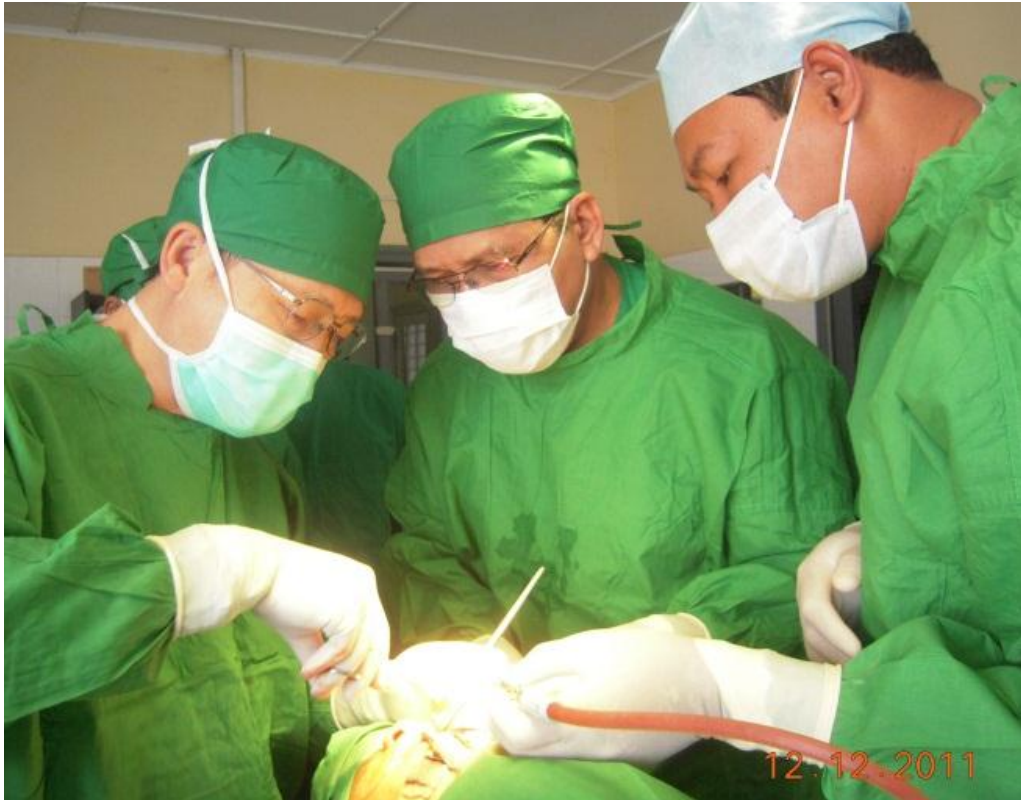**Preoperation preparation – Infusion**



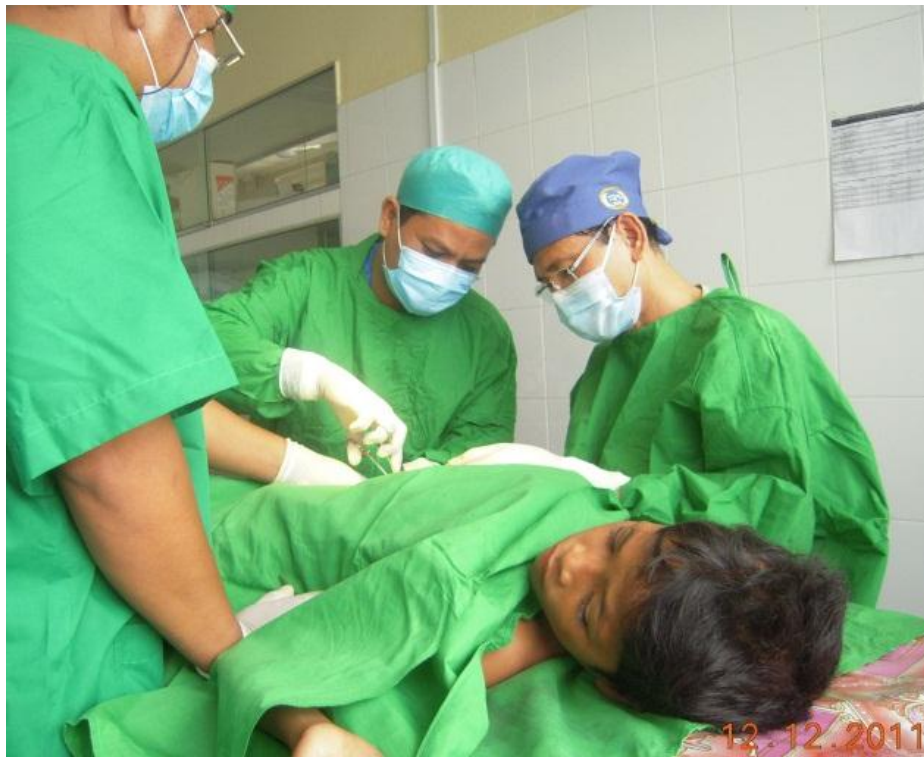Bed Side Surgical Case Discussion – Prior to Surgery



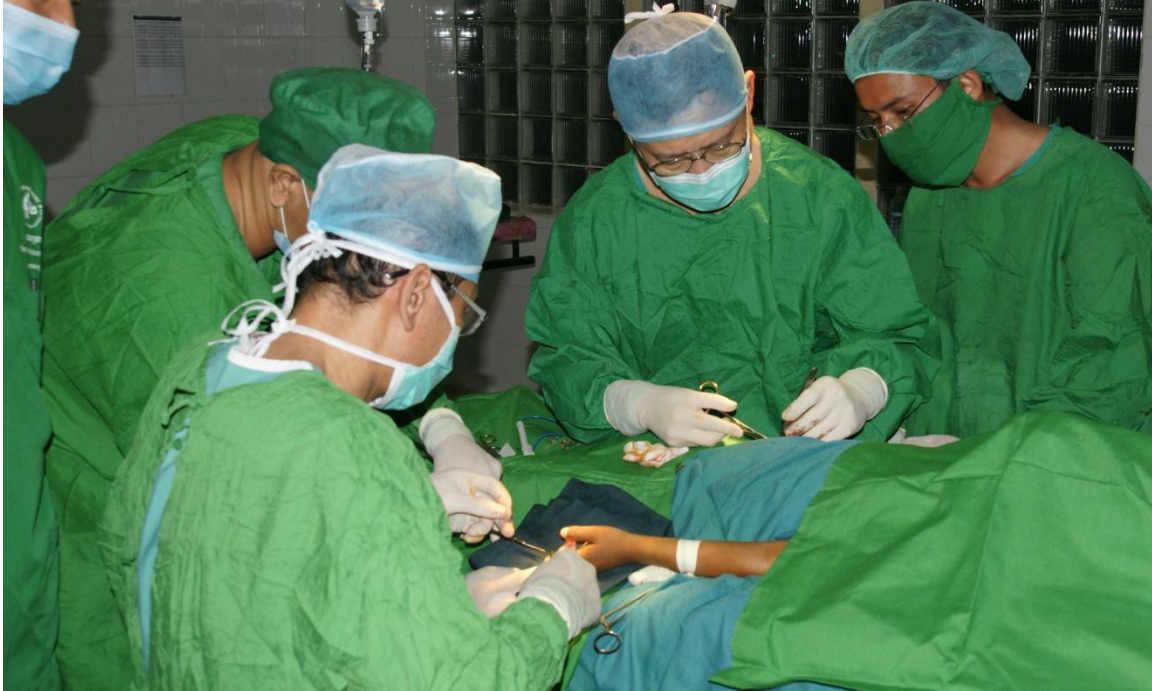Anesthetizing patient – Prior to Surgery



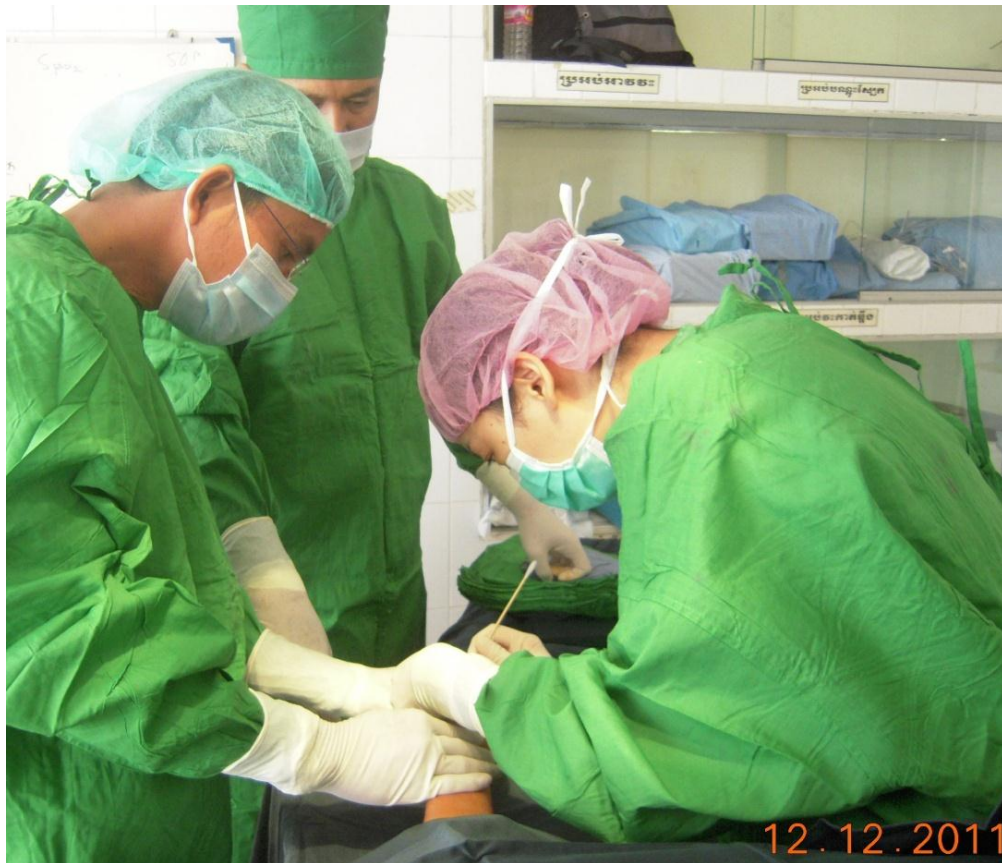Surgical Procedure: – Cleft Surgery



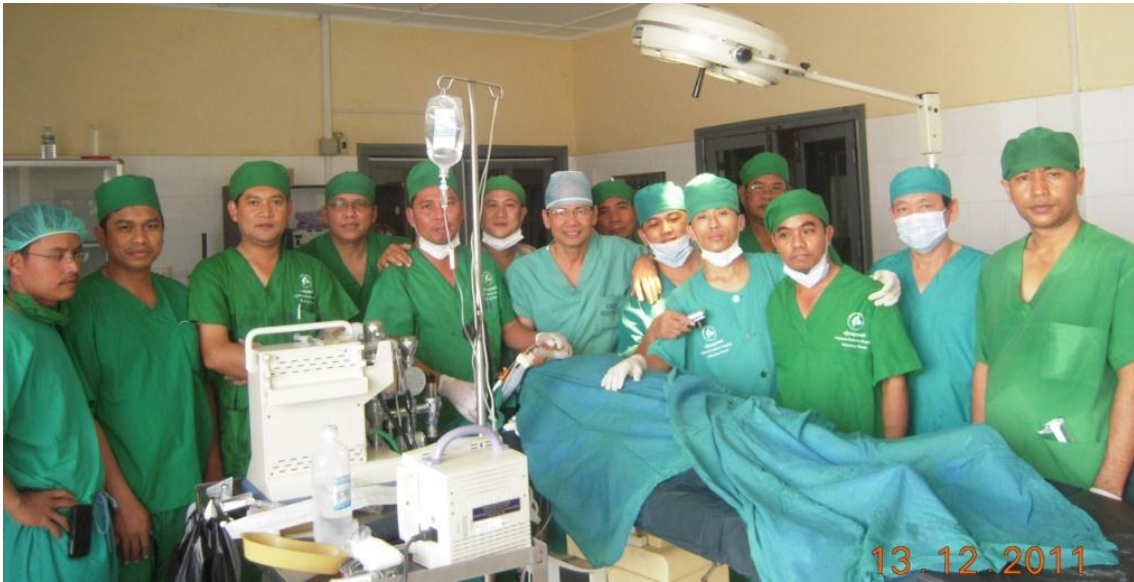Surgical Procedure: – Burn Scar contracture Release-Skin Graft



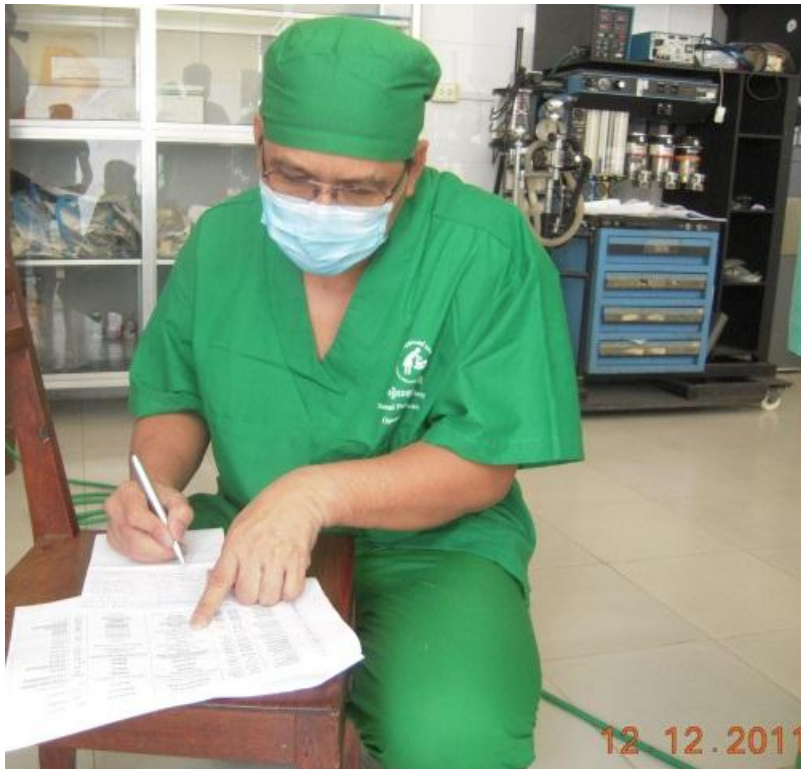Reconstructive Surgery for Syndactyly



Reconstructive Surgery for Finger Burn Scar Contracture



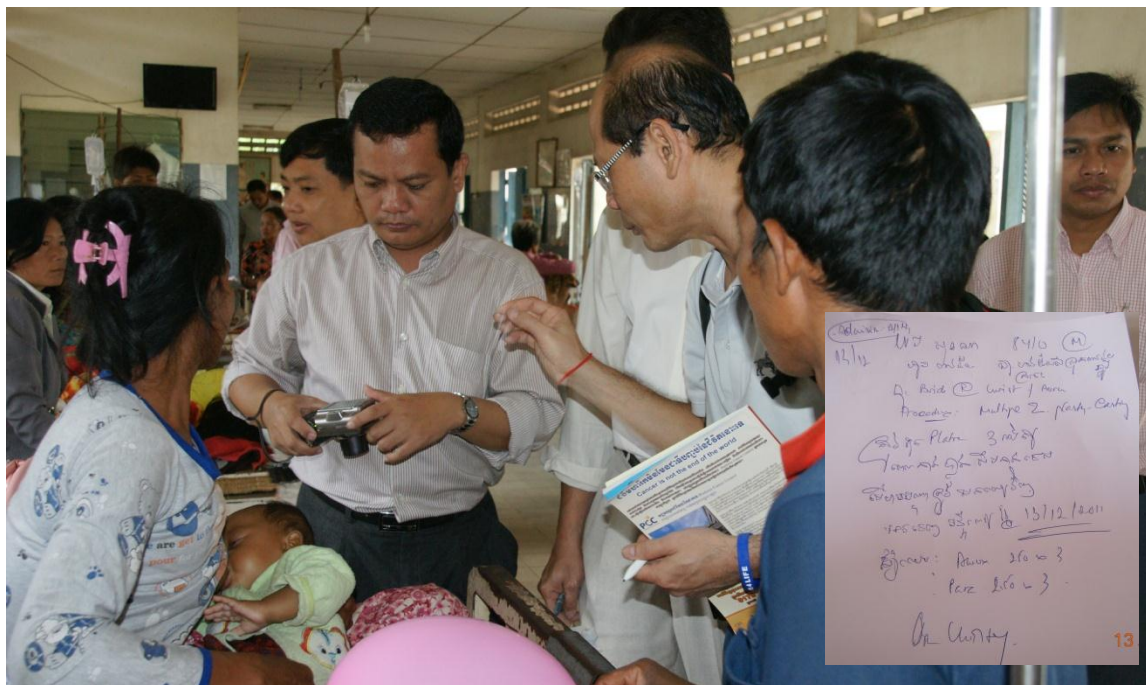The 49<sup>th</sup> Surgical Procedure: Last Case of the Mission: We Are Done !!!



Recording Surgical Procedure – During Surgery



Preoperation Recording – Before Surgery



Recording Surgical Procedure, Recommendation – After Surgery



Ward Round at 8:30 pm after Surgical Operations of the Second Day-Mission



Ward Round with Speech Pathologist



Surgical Team in the patient room, after Ward Round



Moving Stuff back into the Bus at the end of the Mission





Our Mission Is To Provide Smile and Hope To Children  
Suffering of Acute and Chronic Surgical Problems,  
Congenital and Acquired deformities.