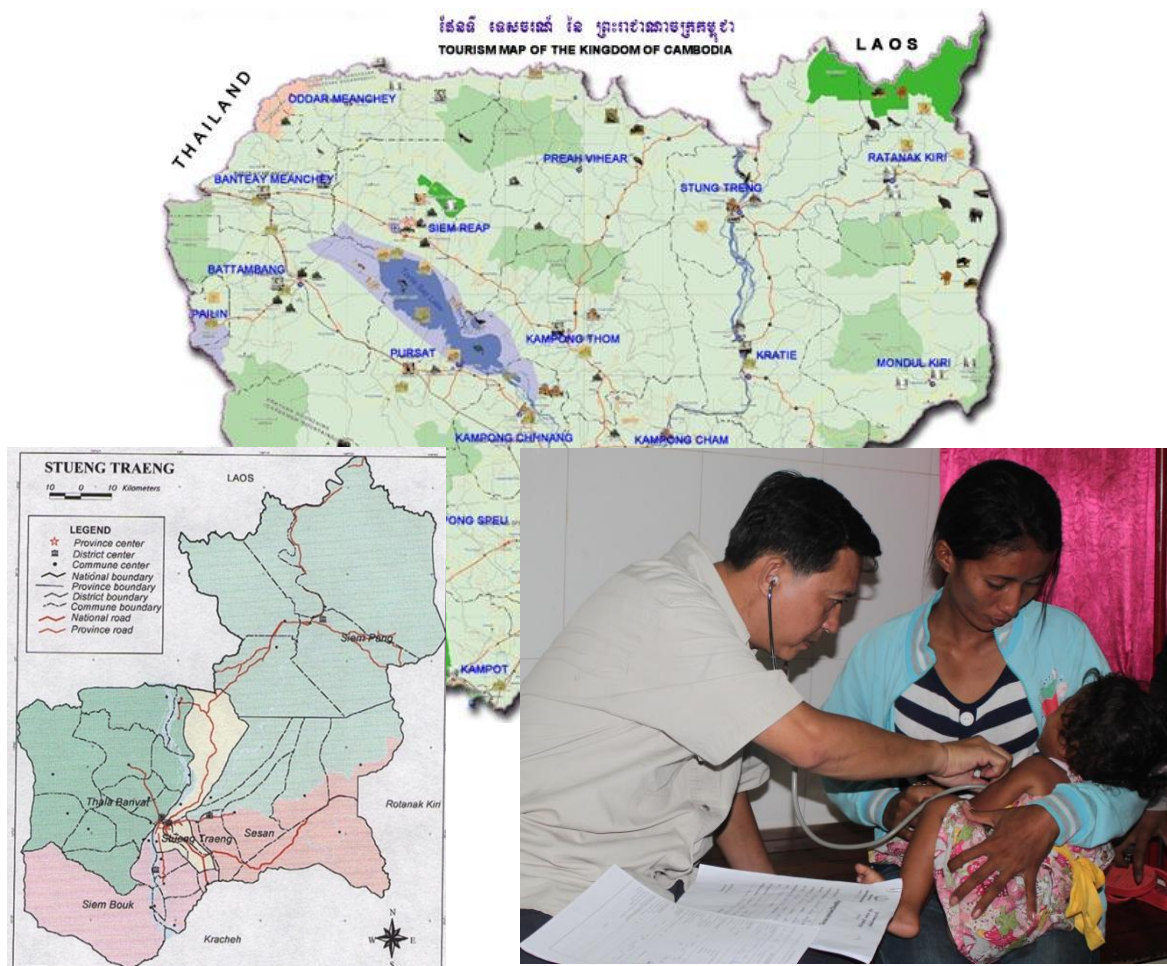


OUTREACH SURGICAL MISSION, STUNG TRENG PROVINCIAL HOSPITAL, CAMBODIA

JUNE 11-14, 2014



Stung Treng is a province in northeast of The Kingdom of Cambodia. Its capital is Steung Treang town. It is located on a high sandy bank overlooking the Mekong River, where it is joined by the Se Kong river. It is 481 km from Phnom Penh and 40 km south of the Laos PDR border. Its 12 016 sq. km is divided into five districts, 34 communes and 128 villages. Stung Treng borders Lao to the north, Ratanakiri to the east, Preah Vihear to the west and Kratie and Kompong Thom to the south.

Stung Treng population is 122,791, male 62,149, and female 60,641. The population in the province includes Khmer, Lao, Chinese, Vietnamese, Kuoy, Khek, Kavet, Phnong, Tumpuon, Lun, Stieng and Prov with Khmer forming the majority. Population density in the province is 13 persons/km². This province is ranked as one of the poorest provinces in Cambodia.

Related to Health System, Provincial Health Department has an operational Districts (OD Steung Treang), a referral Hospitals, 11 Health Centers (only 8 were functioning), and 3 health Posts. It is one of the remote areas in Cambodia, where health services are limited, both facility and techniques.

An outreach surgical mission organized by the department of Surgery of the National Pediatric Hospital, supported by the Connecting with Cambodia Project Rotary Australia World Community Services and Rotary Clubs of Balmoral-Brisbane/Phnom Penh was conducted at Stung Treng provincial hospital. This mission aims to treat children and young adults who suffer from limb and maxillofacial congenital anomalies, burn contractures, and general pediatric surgery, and could not otherwise afford treatment elsewhere.

I- Surgical Team / Man Powers:

Sixteen surgical team members of the National Pediatric Hospital have involved in the mission. These included 3 surgeons, 1 anesthetist doctor, 3 anesthetist nurses, 3 scrub nurses, 2 ward nurses and a coordinator. We have also had 4 surgical trainees joining our mission as assistant.

II- Activities and achievement:

In the morning of June 11, 2014, we departed Phnom Penh and reached Stung Treng provincial hospital at 2:00pm.

We started to do clinical consultation at 2:30pm screening patients for surgery for the 2 following days.

Within 2 working days, we have seen 198 patients coming for consultations and seeking medical advices. Of these 198 patients, 61 patients/cases underwent various surgical procedures.

Patients who received surgical operations included Cleft lip-palate (9 cases), limb deformity (clubfoot, amniotic band) (12 cases), soft tissue tumors (7 cases), Burn contractures of limbs (14), trauma aftermath (4 cases), and inguinal hernia (15 cases).

All procedures, either under local, regional, or general anesthesia were safe and smooth. Immediate post operative status were found no complications.

III- Collaborations:

Local surgical team and hospital direction have been very helpful and facilitating for our mission. They helped us with collecting and registering patients prior to mission dates. They have also helped preparing mission site, both facility and manpower. We have exchanged technical experiences with them, and learned practical things that they have been using with their limited resources to cope with their struggle working condition. Local surgeons will continue taking care operated patients after the mission so that complete healing would be achieved. We are grateful for such an invaluable collaboration which is critical to the success of our surgical mission.

IV- Conclusion:

The mission was considered very successful. Varieties of sixty and one surgical procedures were conducted safely with excellent results. All patients who underwent surgical procedures were satisfied with the results. They are grateful to the surgical team. Local hospital has asked if we could conduct such a surgical mission annually to their province.

V- Acknowledgement:

As the mission coordinator, I would like to express my warm gratitude to all mission members, Stung Treng surgical team, the National Pediatric Hospital Board of Directors, Stung Treng Hospital Director and Stung Treng Provincial Health department for their direct and indirect contribution to this humanitarian surgical mission. We all are grateful to the support from the Connecting with Cambodia project who support this mission.

REPORTED BY

Vuthy CHHOEURN



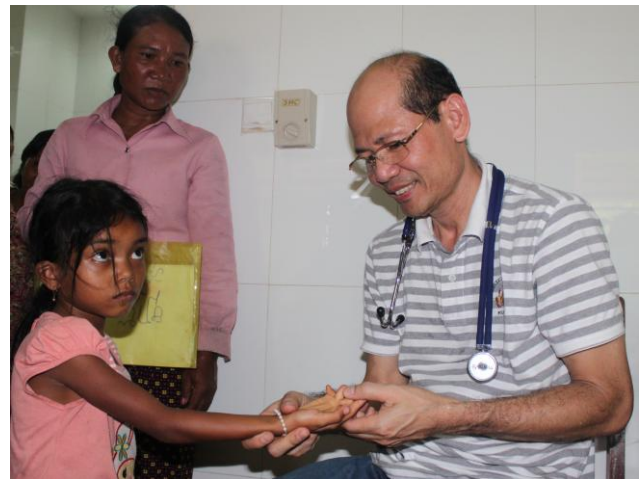NPH surgical Team on its arrival at Stung Treng Provincial Hospital



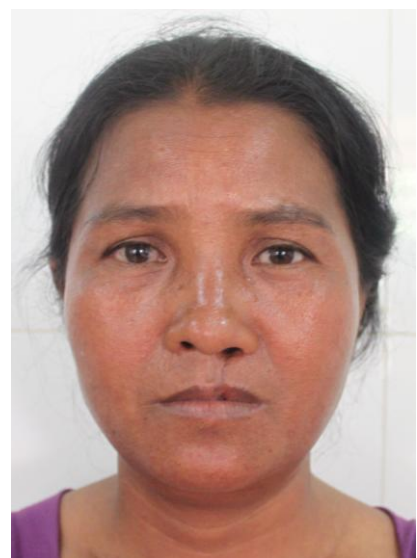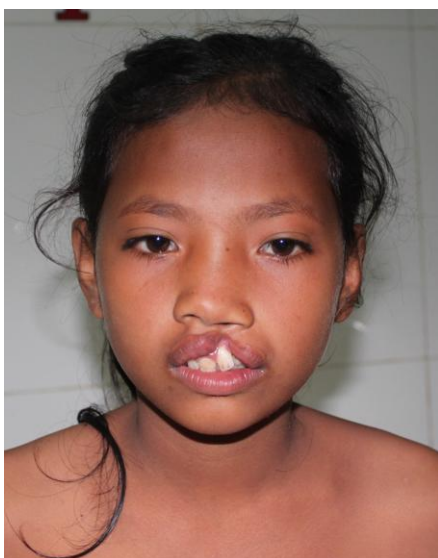Waiting for consultation at mission site



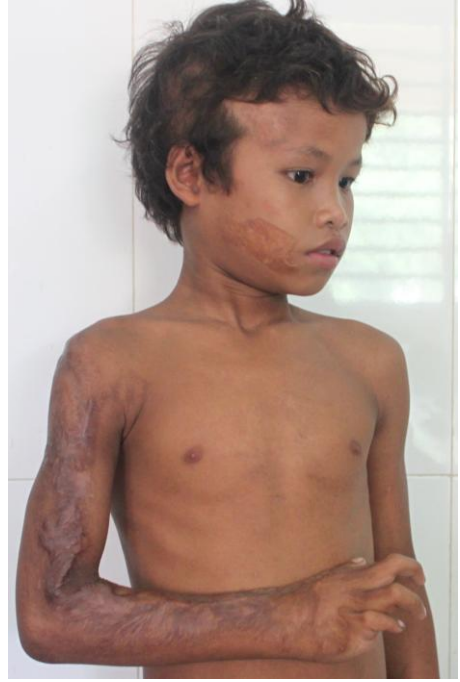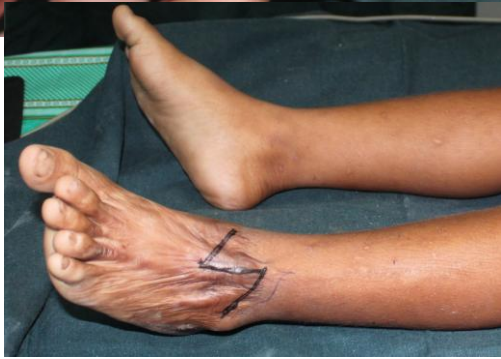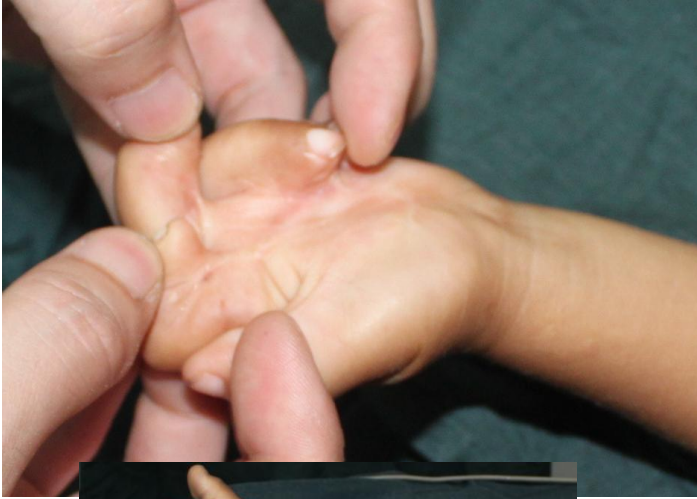Patient consultation on Day 1: 11 June 2014



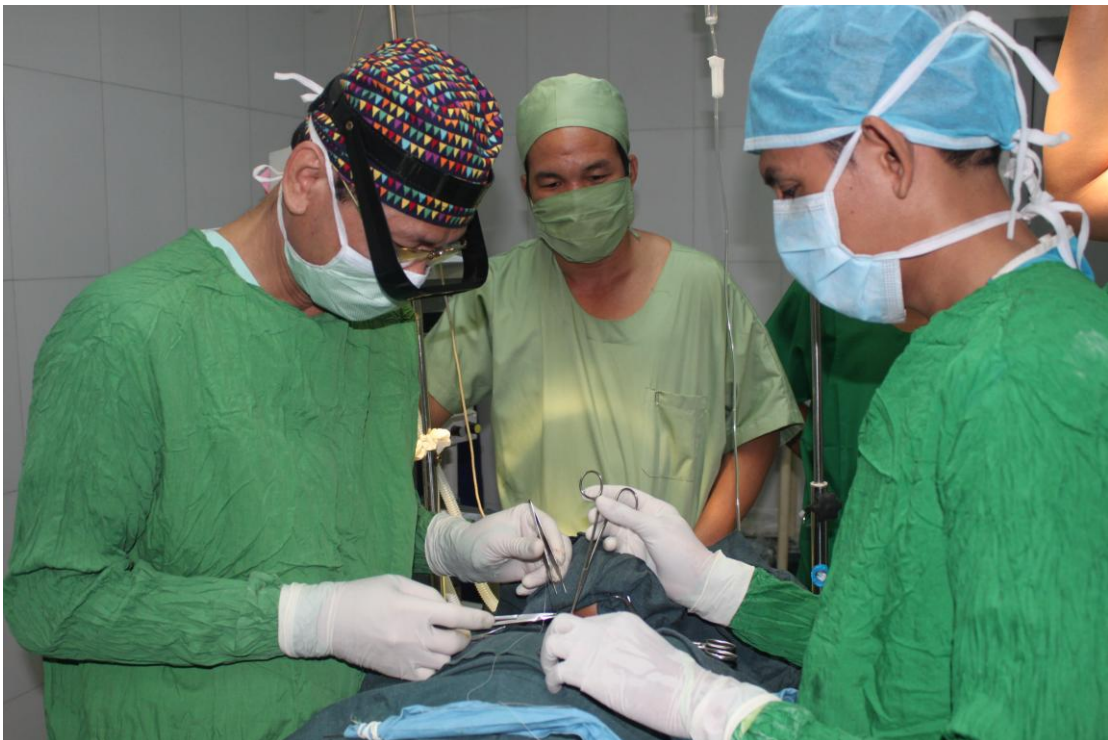Patient consultation: June 11 2014

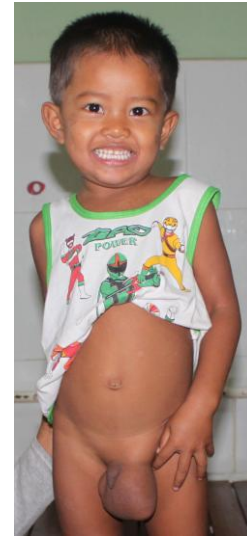
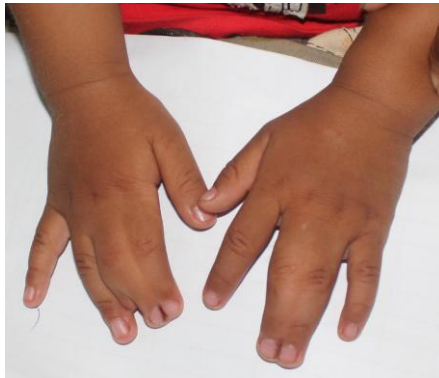
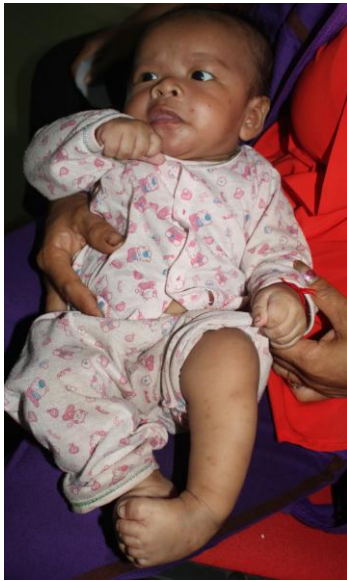Living with **Cleft Palate. Repairs**, while their speeches have already severely affected

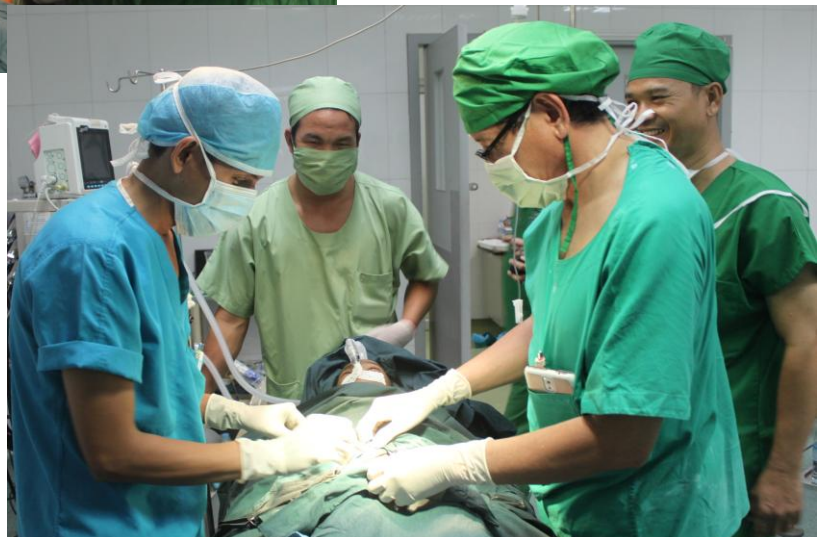
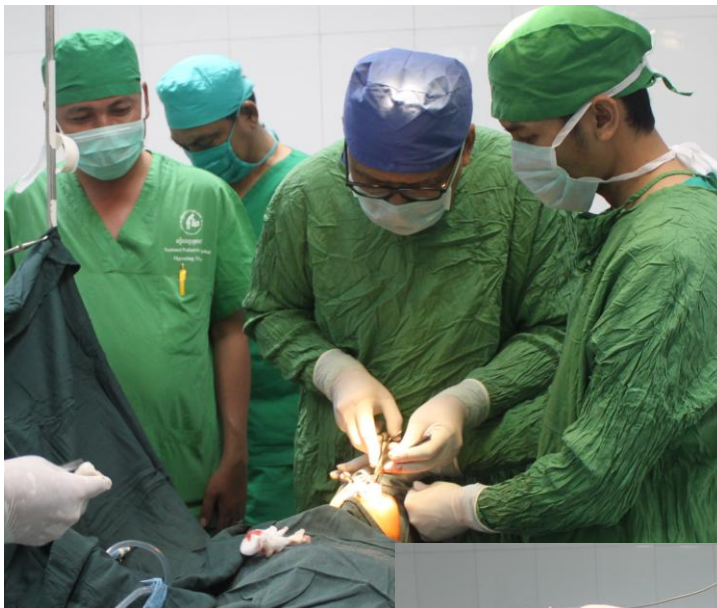
Burn scar contracture released





Varieties of surgical procedures conducting during surgical mission





Missionary Surgical Team

Parents and patients who benefited from the surgical mission would like to express their great thanks to the Connecting with Cambodia Project from Australia (Rotary Australia World Community Services and Rotary Clubs of Balmoral-Brisbane/Phnom Penh) for its invaluable support to make this surgical mission happened.

Such a mission brought Hopes, Smiles, and Happiness to the whole patient family.