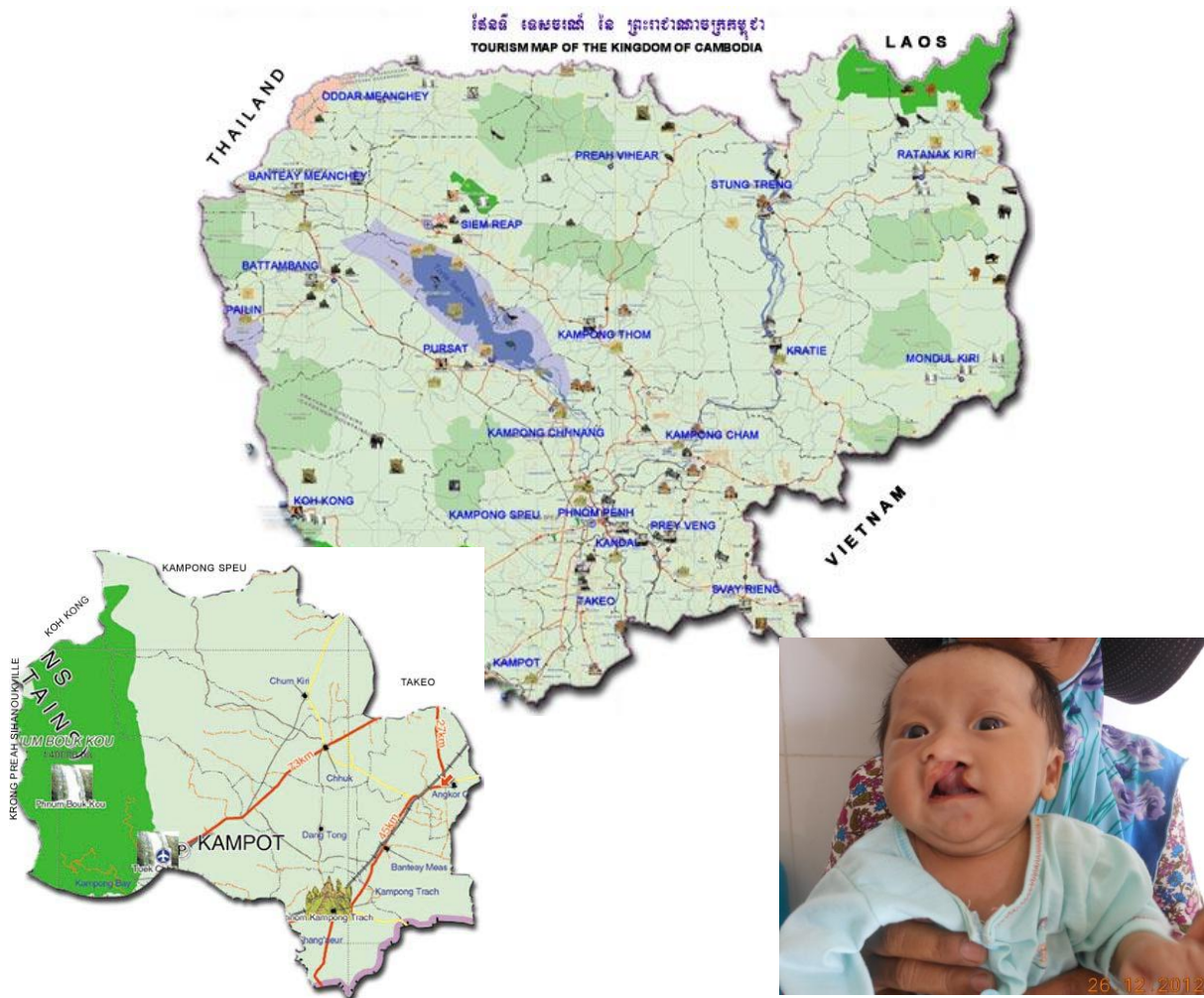


OUTREACH SURGICAL MISSION, KAMPOT PROVINCIAL HOSPITAL, CAMBODIA DECEMBER 26-29, 2012



Kampot is located in Southern Cambodia on the coast of the Gulf of Thailand approximately 148 km from Phnom Penh. It borders Kampong Speu province to the North, Takeo province and Vietnam to the East, the Gulf of Thailand to the South and Sihanoukville and Koh Kong province to the West. The area of the province is 4,873 square kilometers (MAFF www.maff.gov.kh). The topography of the province is variable, from the coastal region on the southern border, to extensive lowland paddy fields and areas of lowland/ upland mosaic to the east and lowland/ upland mosaic and upland forested areas to the west. Kampot is classified as a rural province.

An outreach surgical mission organized by the department of Surgery of the National Pediatric Hospital, supported by the Connecting with Cambodia Project_ Rotary Australia World Community Services and Rotary Clubs of Balmoral-Brisbane/Phnom Penh_, was conducted at Kampot provincial hospital. This mission is to serve children and young adults who suffer from limb and maxillofacial congenital anomalies, and could not otherwise afford treatment elsewhere.

I- Surgical Team / Man Powers:

Thirteen surgical team members of the National Pediatric Hospital have involved in the mission. These included 3 surgeons, 1 anesthetist doctor, 3 anesthetist nurses, 3 scrub nurses, 2 ward nurses and a coordinator. We have also had 5 surgical trainees joining our mission as assistant.

II- Activities and achievement:

In the morning of December 26, 2012, we departed Phnom Penh and reached Kampot provincial hospital at 12:00pm.

We started to see patients at 2:00pm screening for surgery for the 2 following days. During the mission, we have seen 182 patients coming for consultations. These patients were coming from all corners of the province, and some were from neighboring provinces. Of these 182 patients, 32 patients have been scheduled for surgical operations. We have conducted 8 cleft surgeries, 10 reconstructive surgeries secondary to limb congenital deformity, 12 burn and scar contractures, and 2 orthopaedic surgeries. Twelve patients, who need major/complicated surgical care that could not be conducted during the mission, have been documented and sent to specialized hospital in Phnom Penh. Patients who were not candidate for surgery have been treated medically and/or advised further care for their specific problems.

III- Collaborations:

Local surgical team and hospital direction have been very helpful and facilitating for our mission. They helped us with collecting and registering patients prior to mission dates. They have also helped preparing mission site, both facility and manpower. We have exchanged technical experiences with them, and learned practical things that they have been using with their limited resources to cope with their struggle working condition. Local surgeons will continue taking care operated patients after the mission so that complete healing would be achieved. We are grateful for such an invaluable collaboration which is critical to the success of our surgical mission.

IV- Conclusion:


The mission was considered very successful. Varieties of thirty-two surgical procedures were conducted safely with excellent results. All patients who underwent surgical procedures were satisfied with the results. They are grateful to the surgical team. Local hospital has asked if we could conduct such a surgical mission annually to their province. We all are grateful to the support from the Connecting with Cambodia project who support this mission.

REPORTED BY

Vuthy CHHOEURN



NPH surgical Team on its mission to Kampot Province, Midway stopping by along Highway Rd.No 3

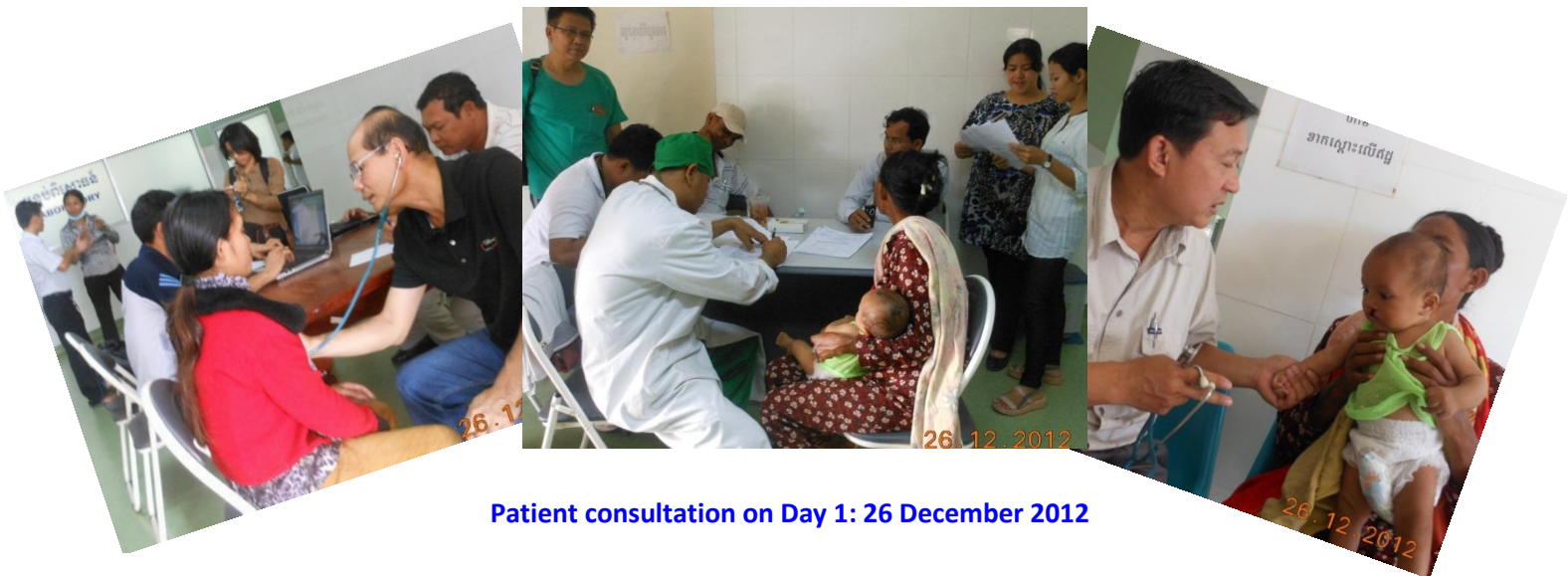

View in front of Kampot provincial hospital- Cambodia, December 2012





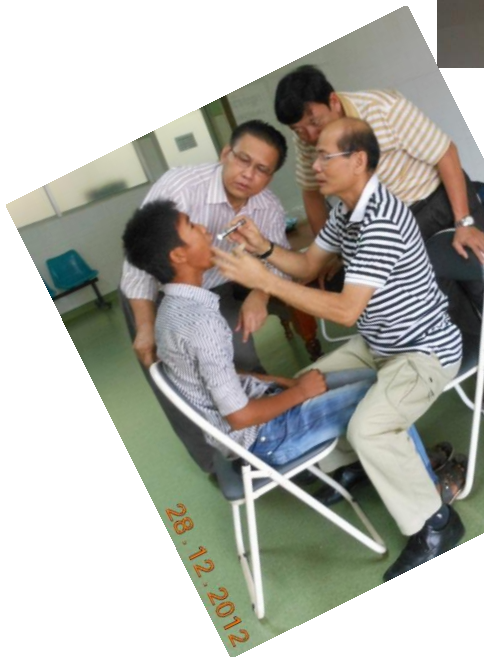Dr. Long Vanna, staff member, is coordinating field work at arrival of the mission site



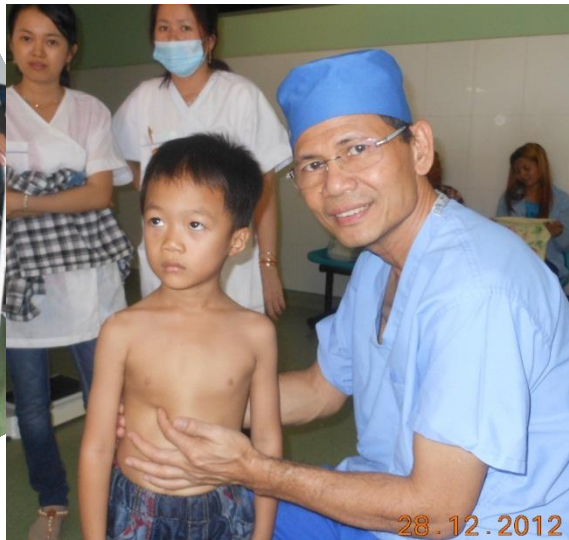Patient consultation on Day 1: 26 December 2012



26.12.2012 17



28.12.2012

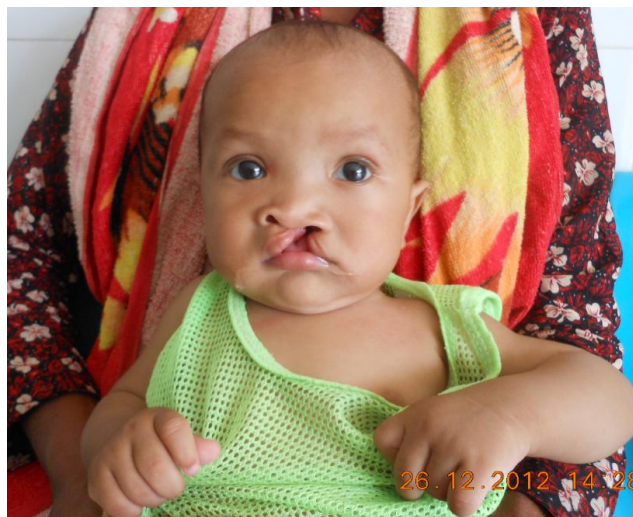

28.12.2012

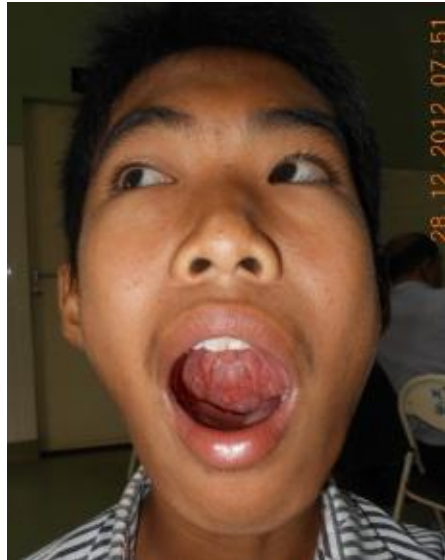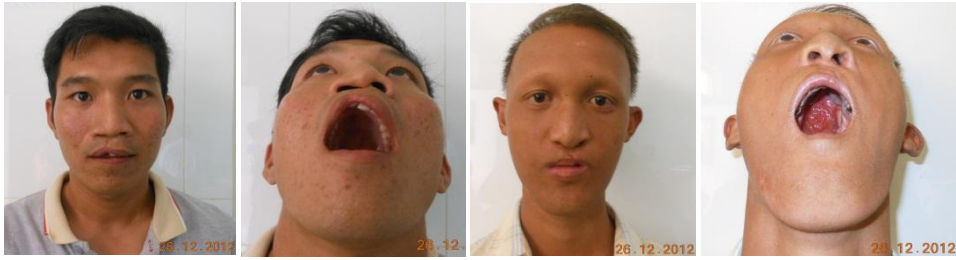Patient consultation: 28 December 2012



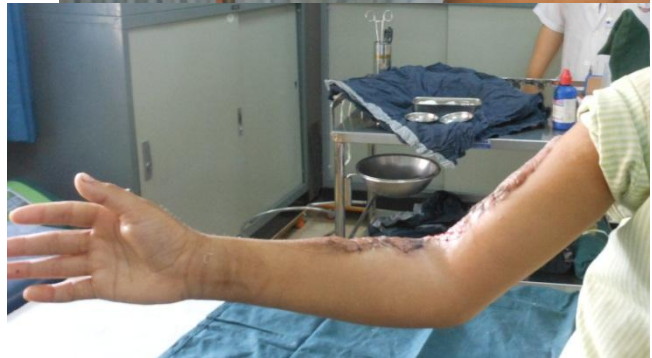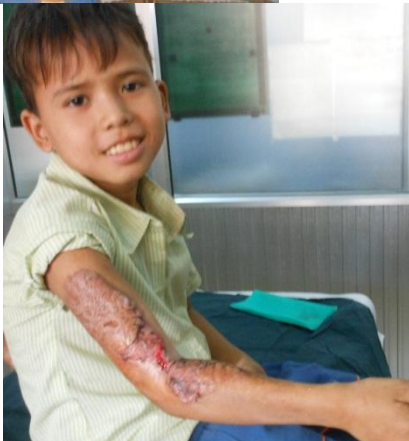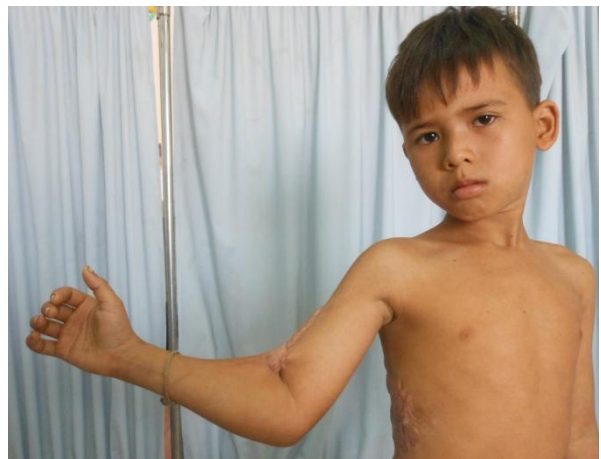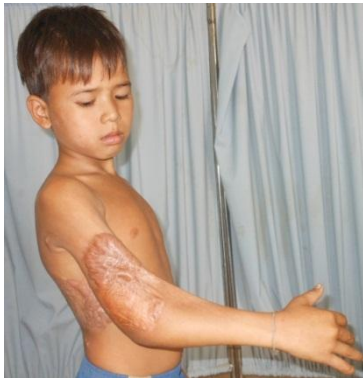28.12.2012



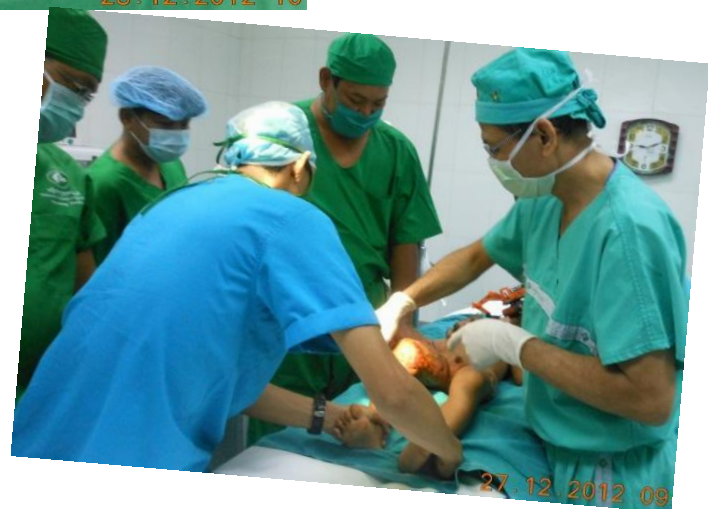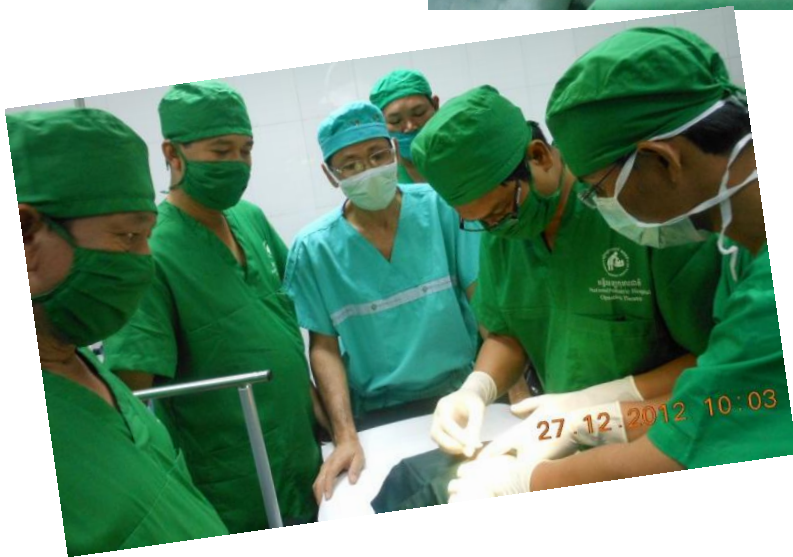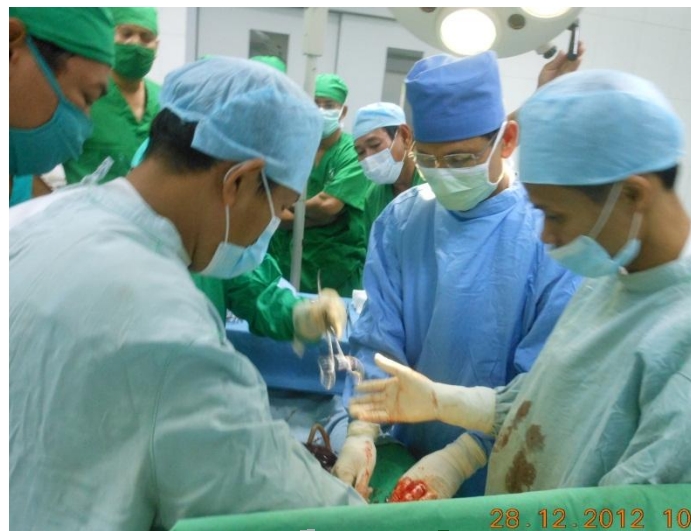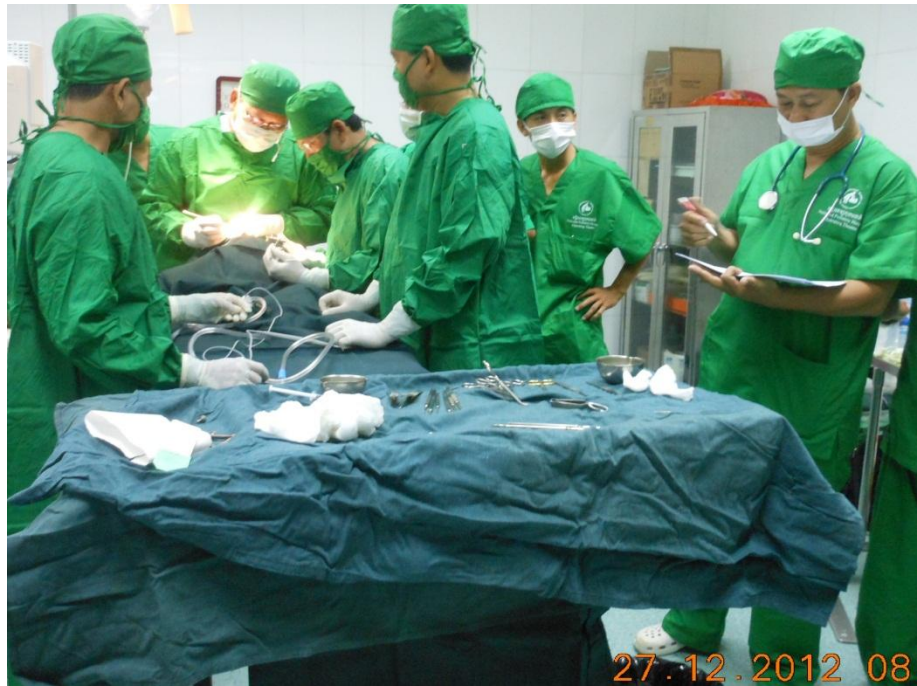26.12.2012 14 28



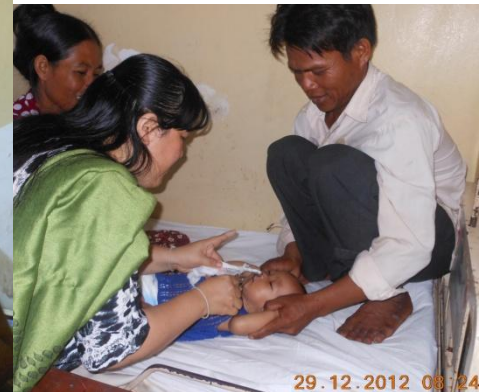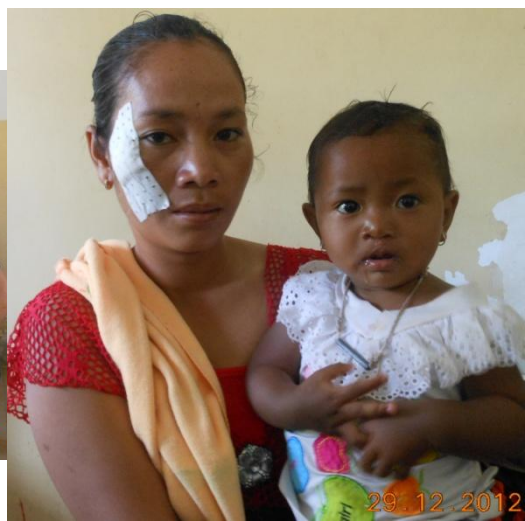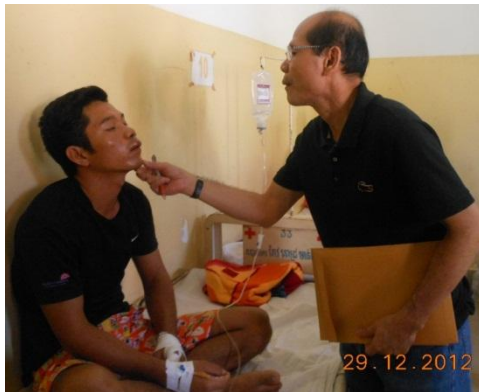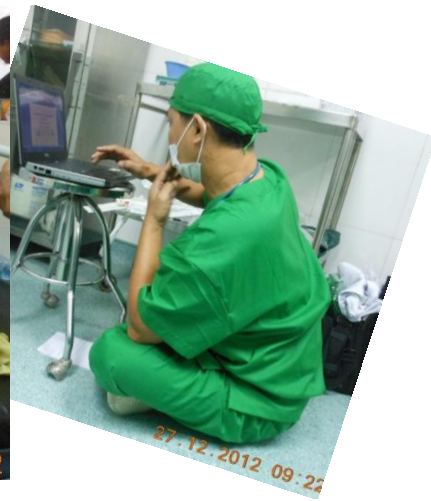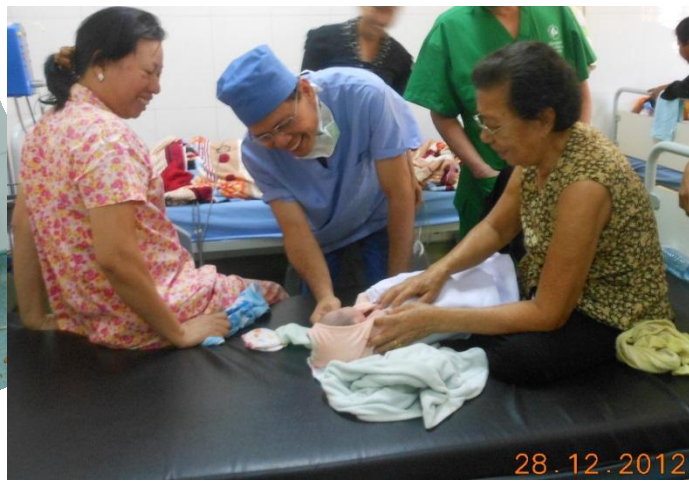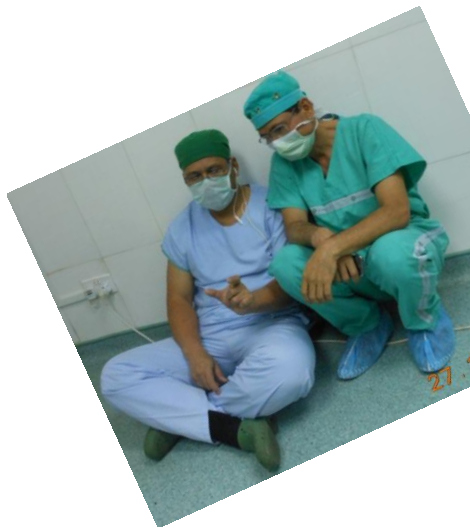These 3 big Kids were waiting for 15 to 17 years to meet our surgical team to have their Cleft Palate Repairs, while their speeches have already severely affected



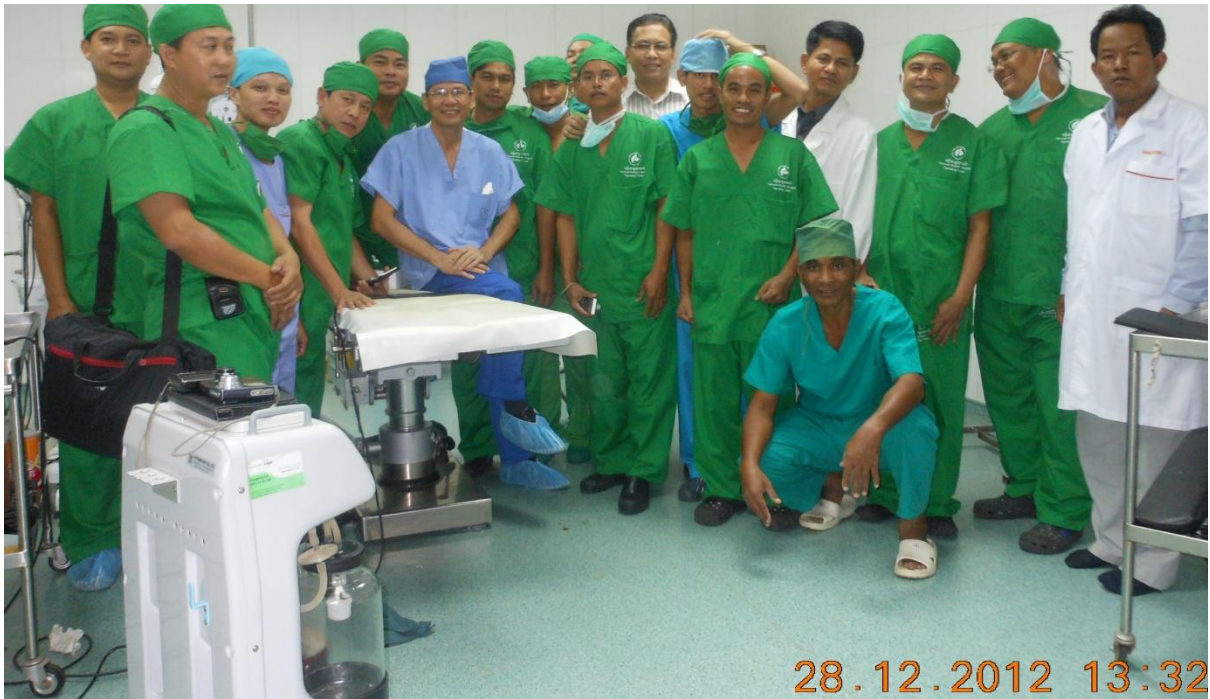This 12 year-old boy who got burn when he was 5 years old, got his burn scar contracture released



Varieties of surgical procedures conducting during surgical mission



Ward round and group photos with operated patients and Parents on the last day of the mission



Missionary Surgical Team



Parents and patients who benefited from the surgical mission would like to express their great thanks to the Connecting with Cambodia Project from Australia (Rotary Australia World Community Services and Rotary Clubs of Balmoral-Brisbane/Phnom Penh) for its invaluable support to make this surgical mission happened.

Such a mission brought Hopes, Smiles, and Happiness to the whole patient family.